

Giacomini vein: thigh extension of the small saphenous vein - report of two cases and review of the literature

Natsis K, Paraskevas G, Lazaridis N, Sofidis G, Piagkou M

Department of Anatomy, Medical School, Faculty of Health Sciences, Aristotle University of Thessaloniki, Thessaloniki Greece.

Abstract

Background: Varicose vein surgery is very commonly performed. Also, it is very frequently employed for recurrent disease. The recognition of the normal or variant veins, inducing incompetency, is a prerequisite for effective treatment. The thigh extension of the small saphenous vein, the so-called Giacomini vein, was extensively described in 1873 by Carlo Giacomini in an incidence of 72%. However, such a vein is usually underestimated in classic surgical textbooks.

Description of cases: We present two cases of Giacomini vein found in two cadavers, dissected for academic purposes in the Department of Anatomy, where the small saphenous vein displayed a thigh extension without terminating into the popliteal vein. In one case Giacomini vein drained into the large saphenous vein, while in the other case the vein divided into two branches, separately draining into the large saphenous vein and the subcutaneous tissue of the gluteal region.

Conclusion: Due to the fact that Giacomini vein could be incompetent, associated with or without varicose saphenous vein trunks, the vascular surgeon should keep in mind that anatomical entity, to include it in preoperative ultrasound scanning control. Moreover, this vein could be utilized as an autologous graft, when the large saphenous is not available. Hippokratia 2015; 19 (3): 263-265.

Keywords: Giacomini vein, small saphenous vein, thigh extension, vein variation

Corresponding Author: Prof. Konstantinos Natsis, Department of Anatomy, Medical School, Faculty of Health Sciences, Aristotle University of Thessaloniki, Thessaloniki Greece, tel : +302310999681, fax : +302310999305, e-mail: natsis@med.auth.gr

Introduction

Varicose veins of the lower limb, especially those involving the large (LSV) and the small saphenous vein (SSV), constitute a well-known venous surgical entity. Since the incompetence of these veins is very common, anatomic knowledge of the common types as well as of their variations, is valuable. In specific, such an important vein variant, often neglected in the classic textbooks, is the so-called Giacomini vein (GV) which represents the proximal extension of the SSV and was described extensively by Carlo Giacomini in 1873. The GV, which constitutes mainly an anastomotic branch between LSV and SSV, has been shown that could be affected by varicose disease with reflux, either upwards or downwards in the thigh¹. Furthermore, GV, due to its frequent occurrence, could be used as an autologous conduit in vascular reconstruction of the lower limb².

The objective of the current study is to present two cases of GV which display interesting morphologic pattern, briefly review its classification systems and assist the physician in the accurate interpretation of surgical and ultrasound scanning findings that correspond to the not so well-known GV.

Case 1

During the gross anatomy course for second-year

medical students at the Department of Anatomy, we came across an SSV variant on the posterior aspect of the right thigh in a 79-year-old Greek male cadaver. In specific, by means of the classic method of anatomic dissection and after removing the skin and the subcutaneous tissue of the right lower limb, we observed that the SSV did not terminate into the popliteal vein. It coursed between the long head of biceps femoris muscle and the other posterior thigh muscles following an arcuate direction medially, and finally terminated into the LSV at the junction of the upper and middle third of the ipsilateral thigh (Figure 1).

Case 2

During the educational course at the Department of Anatomy, in an embalmed 84-year-old Greek female cadaver, we found a proximal thigh extension of the right SSV, the so-called GV. In particular, we noticed that the SSV did not display saphenopopliteal junction, but it was directed upwards, and at the medial border of the musculotendinous junction of the ipsilateral semitendinosus muscle, it was divided into two branches, a lateral and a medial one. The lateral branch directed almost vertically, draining into the subcutaneous tissue of the right gluteal region, whereas the medial branch coursed obliquely to terminate into the LSV (Figure 2).

According to the medical records of these specimens, no chronic venous disease or other previous vascular procedures were mentioned and the cause of death was unrelated to the current study findings.

Discussion

Defining GV is a controversial issue in the medical literature. Carlo Giacomini, in his original study, referred to the proximal thigh extension of the SSV and described the following eight types: i) An anastomotic branch between LSV and SSV with the latter terminating into the popliteal vein (52.94%). ii) A large sciatic nerve satellite vein terminating into the subcutaneous tissue of the posterior thigh, with the SSV draining into the popliteal vein (13.73%). iii) A voluminous SSV branch communicating with the third perforator while the SSV terminated into the popliteal vein (1.96%). iv) Various small SSV branches draining into perforators (3.92%). v) The entire SSV draining via a certain anastomotic channel into the LSV (13.73%). vi) Main termination into the SSV and partially into the short head of biceps femoris muscle, with small anastomotic rami to the LSV (5.88%). vii) The entire SSV terminating into the short head of biceps muscle (1.96%). viii) The entire SSV terminating into the popliteal vein, where no thigh extension was noticed (5.88%)^{1,2}.

Georgiev distinguished three types of proximal thigh extension of the SSV: i) the femoropopliteal vein joining the proximal portion of the LSV, as a posteromedial branch of the SSV, ii) GV representing the oblique intersaphenic anastomosis, which connects either the SSV or the femoropopliteal vein with the LSV, and iii) the thigh SSV terminations, in which the SSV runs upwards for 5-10 cm above the popliteal crease bending inward in depth between the thigh muscles³. Delis et al classified the proximal extension of the SSV as: a) high, when the SSV junction with the deep venous system occurs at a distance of 7-12 cm above the popliteal skin crease, b) very high, when the SSV extends beyond 12 cm above the popliteal crease, and c) as GV when the SSV ascends in the thigh, 12 cm above the popliteal crease, irrespectively of the SSV point of termination⁴.

Schweighofer et al classified the following five types of saphenopopliteal junction (SJ): a) Large and distinct SJ with thin SSV's thigh extension (37.2%). b) Thin SJ with large SSV thigh extension (15.1%). c) Absence of SJ with prominent SSV thigh extension (24.4%). d) Doubled SJ with evident SSV thigh extension (5.8%). e) Web style SJ with distinct SSV thigh extension (17.4%)⁵. Kosinski observed the following types: Type 1a (42%), with exclusive termination into the SSV. Type 1b (15.3%) where

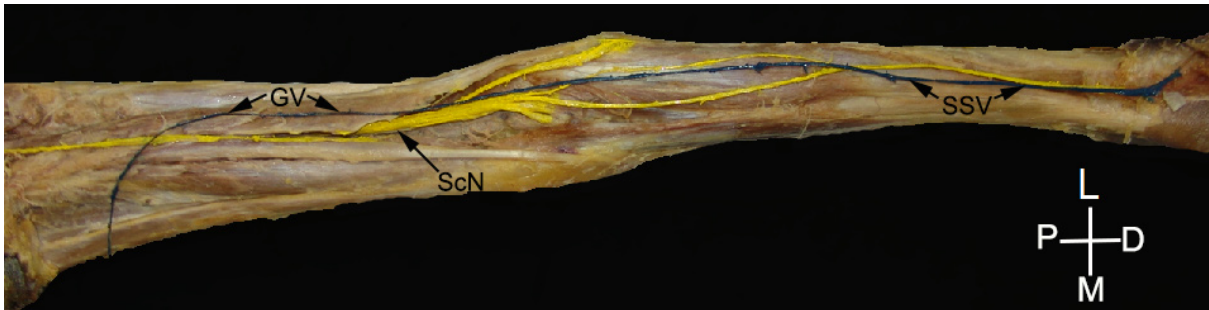

Figure 1: The posterior aspect of the right lower limb has been dissected, demonstrating the small saphenous vein (SSV) not terminating into the popliteal vein, but into the large saphenous vein as Giacomini vein (GV).

ScN: Sciatic nerve, P: proximal, D: Distal, L: lateral, M: medial.




Figure 2: A) The posterior aspect of the right lower limb is seen, where the small saphenous vein (SSV) does not display saphenopopliteal junction continuing as a Giacomini vein (GV). The latter one divides into a lateral branch (Lat Br) draining into the subcutaneous tissue of gluteal region and a medial branch (Med Br) draining into the large saphenous vein (*: semitendinosus muscle). B) On the anterior aspect of the right femur of the same cadaver, Giacomini vein (arrows) is demonstrated draining into the large saphenous vein (LSV).

***: Sartorius muscle, P: proximal, D: distal L: lateral, M: medial.

SSV divides into two branches, one draining into the popliteal vein and the other into the LSV. Type 2a (13.7%) where the vein entirely terminates into the posterior veins of the thigh. Type 2b (6.4%) where SSV is divided into two branches, at the level of popliteal fossa, one draining into the LSV and the other one into the posterior thigh muscles. Type 2c (12.9%) with a direct termination of the SSV into the LSV. Type 3a (9.7%) with SSV terminating into the LSV. Type 3a (9.7%) where SSV terminates into the LSV, below the knee joint. Type 3b (1.6%) with SSV termination being the intragastroneurial veins⁶.

In 2001, the International Union of Phlebology, supported by the Federative International Committee on Anatomical Terminology, provided a new terminology for the superficial veins of the lower extremity. In that list of veins, one may notice the term “cranial extension of the SSV” as well as the term “intersaphenous vein” that corresponds to what is designated as GV⁷. In the first edition of *Nomina Anatomica* which was held in Basle in 1895⁸, the term “femoropopliteal vein” was used for the communicating vein between the SSV and the LSV, coursing on the posteromedial aspect of the leg, whereas in later editions of *Terminologia Anatomica* the aforementioned term was replaced by the term “accessory saphenous vein”⁹.

GV's prevalence varies widely between 2%, as detected in duplex scanning¹⁰ and 95%, as detected in post-mortem studies¹¹, whereas its diameter range is between 0.2 to 7.7 mm⁴. GV displays three sections, a distal and a proximal one, under the fascia and a middle section that runs subcutaneously. Delis et al observed a single termination of GV in 86.8%, a dual termination in 12.7% and a triple termination in 0.5%, with GV terminating most often into the LSV (49.5%) and less often into the posterior thigh muscle veins⁴. Thus, GV may terminate into the LSV, the posterior thigh muscle veins, the femoral vein or even, more rarely, into branches of the internal iliac vein, such as the inferior gluteal or internal pudendal vein^{3,4,10}. It has been postulated that GV along with the SSV are the same vein, as they develop from the same primitive vessel following the course of the accompanying nerve and running into the same interfascial compartment¹².

The GV we present in the first reported case corresponds to a pattern which appears with an incidence of 14%, according to Giacomini. The second case we report is rarely mentioned in the literature and was not included by Giacomini in his investigation. We observed a GV dividing into two venous channels, one terminating into the LSV and the other one into the subcutaneous tissue of the gluteal region and presumably into the inferior gluteal vein. Farrah et al reported SSV draining into tributaries of the internal iliac vein in less than 2.2% of their patients¹⁰. The second reported case is different from Kosinski's type 2b classification because the vein is undivided in the popliteal fossa, and moreover, the lateral branch terminates into the subcutaneous tissue of the gluteal region instead of the posterior deep veins of the thigh.

Giacomini noticed the presence of two valve arrangement in the lumen of the vein, one permitting upward

flow, in the case of intersaphenous anastomosis and the other permitting downward flow, in the case of thigh extension of the SSV. In the latter case when valves become incompetent a “paradoxical” varicose vein pattern may appear, since GV is filled with an anti-gravitational upward reflux¹. In order to achieve an uneventful surgical outcome, vascular surgeons should be aware of the type of termination and the presence of any vein incompetence as well. Delis et al found that reflux was present in 4.7% in GV patients and also noted that venous incompetence pertaining to the saphenous trunks was significantly higher in comparison to GV incompetence⁴. Farrah et al reported that in 18% of patients with SJ incompetence, either a GV or a gastrocnemius vein incompetence was also present¹⁰. Moreover, GV is worth considering in the reconstruction of the lower limb arteries, in patients with unavailable LSV².

In the light of the above mentioned, vascular surgeons should bear in mind the possible presence of GV with or without SJ and take into account that GV may be incompetent regardless of any coexisting saphenous trunk incompetence. Thus, a duplex ultrasound scanning, prior to any surgical intervention on the lower extremity, should be performed in order to unveil the possible presence of GV in chronic venous disease patients.

Conflict of interest

The authors declare no conflict of interest.

References

- Georgiev M, Myers KA, Belcaro G. The thigh extension of the lesser saphenous vein: from Giacomini's observations to ultrasound scan imaging. *J Vasc Surg.* 2003; 37: 558-563.
- Delis KT, Swan M, Crane JS, Cheshire NJ. The Giacomini vein as an autologous conduit in infrainguinal arterial reconstruction. *J Vasc Surg.* 2004; 40: 578-581.
- Georgiev M. The femoropopliteal vein. *Ultrasound anatomy, diagnosis, and office surgery. Dermatol Surg.* 1996; 22: 57-62.
- Delis KT, Knaggs AL, Khodabakhsh P. Prevalence, anatomic patterns, valvular competence, and clinical significance of the Giacomini vein. *J Vasc Surg.* 2004; 40: 1174-1183.
- Schweighofer G, Mühlberger D, Brenner E. The anatomy of the small saphenous vein: fascial and neural relations, saphenofemoral junction, and valves. *J Vasc Surg.* 2010; 51: 982-989.
- Kosinski C. Observations on the Superficial Venous System of the Lower Extremity. *J Anat.* 1926; 60: 131-142.
- Mozes G, Gloviczki P. New discoveries in anatomy and new terminology of leg veins: clinical implications. *Vasc Endovascular Surg.* 2004; 38: 367-374.
- His W (ed). *Die Anatomische Nomenclatur, Nomina Anatomica.* Verlag von Veit und Comp, Leipzig, 1895, 78.
- Whitmore I (ed). *Terminologia Anatomica.* International Anatomical Terminology. Federative Committee on Anatomical Terminology. Thieme, Stuttgart, 1998, 98.
- Farrah J, Saharay M, Georgiannos SN, Scurr JH, Smith PD. Variable venous anatomy of the popliteal fossa demonstrated by duplex scanning. *Dermatol Surg.* 1998; 24: 901-903.
- Stolic E. [Posterior subaponeurotic vein of the thigh]. *C R Assoc Anat.* 1970; 149: 1016-1026.
- Gillot C. Post-axial extension of the short saphenous vein: anatomical study, functional considerations, pathological significance. *Phlebologie.* 2000; 12: 107-111.