CASE REPORT

Hypercalcemia and multiple osteolytic lesions in an adult patient with relapsed pre-B acute lymphoblastic leukemia: a case report

Kaiafa G[1], Perifanis V[1], Kakaletsis N[1], Chalvatzi K[2], Hatzitolios AI[1]

[1]First Propedeutic Department of Internal Medicine
[2]Department of Immunology, Laboratory of Microbiology,
AHEPA University Hospital, Medical School, Aristotle University of Thessaloniki, Thessaloniki, Greece

Abstract

Background: Hypercalcemia and severe osteolytic lesions are rare complications of acute lymphoblastic leukemia (ALL) in childhood, and those cases share similar clinical features. Similarly, hypercalcemia is a rare feature in adult ALL. Here, we report an uncommon case of an adult patient with relapsed precursor B ALL (pre-B ALL) who developed multiple osteolytic lesions and hypercalcemia.

Case description: A 24-year-old male patient, diagnosed with pre-B ALL, was admitted in our hospital due to severe lumbar pain. After reviewing laboratory, radiological and clinical findings, the patient was diagnosed as having relapse of a mixed phenotype acute leukemia, according to bone marrow aspiration (9% blasts) and cytogenetic analysis, with multiple osteolytic lesions in all lumbar vertebrae, sacrum and ilium and severe hypercalcemia (13.3 mg/dL). Thus, FLAG-IDA rescue therapy and hydration plus furosemide, corticoids and bisphosphonates were administered. Despite initial amelioration, his hematological condition deteriorated and he died due to severe sepsis as a result of severe immunosuppression.

Conclusion: Two possible mechanisms have been suggested for hypercalcemia in hematological malignancy, either the leukemic infiltration or the paraneoplastic production of a variety of humoral factors and proinflammatory cytokines. However, hypercalcemia and severe osteolytic lesions are rare features in ALL adult patients and their combination may be indicator of poor prognosis. Hippokratia 2015, 19 (1): 78-81.

Keywords: Precursor B acute lymphoblastic leukemia, relapse, hypercalcemia, osteolysis, multiple osteolytic lesions, adult

Corresponding Author: Nikolaos Kakaletsis, First Propedeutic Department of Internal Medicine, Medical School, Aristotle University of Thessaloniki, AHEPA University Hospital, 1 Stilponos Kyriakidi Street, 54636, Thessaloniki, Greece, tel: +30 2310994783, fax: +30 2310994773, e-mail: kakaletsisnikos@yahoo.gr

Introduction

Acute lymphoblastic leukemia (ALL), being the most common malignancy in children, is a relatively rare neoplasm in adults. ALL is more common in men than in women and about 10,000 new cases are diagnosed in Europe each year, which represents about 15% of leukemias in adults. Its diagnosis can be established when the bone marrow examination reveals a lymphoid blast cell content in excess of 20% of total cellularity. Precursor B ALL (pre-B ALL) is defined by the positive reaction (>20%) for any two of the earliest B-lineage markers (CD19, CD79a, CD22) or plus CD10 antigen with additional identification of cytoplasmatic IgM (cytIgM)[1].

Hypercalcemia and severe osteolytic lesions are rare complications of ALL in childhood and adolescence and these cases are suggested to share similar clinical features, such as age (10-20 years) and normal white cell count with absent or rare circulating blasts[2]. In contrast, hypercalcemia in adults is often presented in hematological malignancies, such as multiple myeloma or adult T-cell lymphoma/leukemia but it is a rare feature in adult ALL. Paraneoplastic production of a variety of humoral factors and proinflammatory cytokines have been shown to be involved in osteoclastic bone resorption causing hypercalcemia in malignant disorders, such as parathyroid hormone related protein (PTHrP), prostaglandin E_2, tumor necrosis factor (TNF)-a, TNF-b, interleukin (IL)-1b and IL-6[3].

We report the case of a 24-year-old male patient with relapsed pre-B ALL who developed multiple osteolytic lesions and hypercalcemia and we discuss their possible underlying mechanisms.

Case report

A 24-year-old male patient, who had been diagnosed with pre-B ALL (May 2010), was admitted in our hospital due to severe lumbar pain (December 2012). During his initial diagnosis, the patient had undergone 8 cycles of the intensive chemotherapy regimen Hyper-CVAD (cy-

Table 1. Natural history of precursor B acute lymphoblastic leukaemia, in our 24-year-old male patient, from the moment of its diagnosis until his death.

Date	Clinical symptoms	Blood test	Blast's immunohistochemical analysis	Cytogenetic analysis	Cerebrospinal fluid analysis	Diagnosis	Treatment
May 2010	Pleurodynia	WBC: 7.7x10^9/L (1% blasts), Hb: 8.9g/dL, PLT: 67x10^9/L, LDH: 1041U/L, albumin 4.73g/dL, CRP: 1.62mg/dL, β2-microglobulin: 2.95 mg/L	40% blasts (bone marrow aspiration) **Positive (+):** CD45 (100%), CD34 (83%), CD19 (85%), CD10 (93%), CD22 (90%), CD38 (64%), CD13 (42%), Tdt (49%), CD79a (85%), cytIgM (33%) **Negative (-):** CD20, CD33, HLA DR, MPO, sIg	Normal	Normal	pre-B ALL	hyper–CVAD (8 cycles) and intrathecal infusions
May 2011	Left hip joint pain	WBC: 4.1x109/L Hb 15.5g/dL, PLT: 188x10^9/L, LDH: 337U/L albumin: 4.87g/dL	Complete remission	N/A	N/A	Bilateral avascular necrosis of the femur head	discontinue corticosteroids of the maintenance chemotherapy
May 2012	Dyspnea and fever (40°C)	WBC: 9.6x10^9/L Hb 16.6g/dL PLT: 299x10^9/L LDH: 280U/L, albumin: 4.57g/dL	0.02 blasts (peripheral blood) **Positive (+):** CD45, CD19 CD10, CD34, CD38	N/A	N/A	Lower respiratory tract infection	linezolid, piperacillin/ tazobactam, fluconazole
Dec. 2012	Severe lumbar pain	WBC: 8.8x10^9/L, Hb: 17.4g/dL PLT: 130x10^9/L, LDH: 404U/L, albumin 5.05g/dL CRP: 4.5mg/dL β2-microglobulin: 3.6 mg/L	9% blasts (bone marrow aspiration) **Positive (+):** CD19 (100%), CD10 (45%), iCD22 (40%), Tdt (68%), iCD79a (62%), CD34 (100%), CD38 (68%), HLA DR Additional antigens CD11b (12%) CD13 (15%) and iMPO (28%)	46,XY,dup(1) (q21q32), del(8) (p22)[12]/46 XY[8]	Normal	Disease relapse hypercalcaemia and multiple osteolytic lesions bilateral meralgia paresthetica died from sepsis	FLAG-IDA rescue therapy

WBC: white blood cells, Hb: hemoglobin, LDH: lactate dehydrogenase, CRP: C-reactive protein PLT: Platelets, pre-B ALL: precursor B acute lymphoblastic leukaemia, N/A: Not available, CD: cluster of differentiation.

clophosphamide, vincristine, adriamycin, and dexamethasone, alternately with methotrexate and cytarabine) and intrathecal infusions of alternately methotrexate and cytarabine. Since an HLA-compatible donor could not be found, maintenance chemotherapy was administered [mercaptopurine per os 75 mg/m^2 daily, vincristine Intravenous (iv) 2 mg monthly, prednisolone iv 4 mg for five days per month, methotrexate iv 20 mg/m2 per week], followed by complete remission for twenty three months (January 2011 to December 2012). His medical history, was also remarkable for bilateral avascular necrosis of the femoral head (May 2011) detected by computed tomography scan and resulting in discontinuation of corticosteroids and for hospitalization (May 2012) for lower respiratory tract infection (Table1).

Laboratory data were as follows, white blood cells: 8.8 x 10^9/L without blasts, hemoglobin: 17.4 g/dL, platelets: 130 x 10^9/L, urea: 47 mg/dL, creatinine: 1.61 mg/dL, glomerular filtration rate to 53 mL/min/1.73 m2, calcium: 13.3 mg/dL, phosphorus: 5.3 mg/dL, uric acid: 9.7 mg/dL, vitamin 1,25(OH)$_2$D: 21.8 (range 15-60) pgr/mL, vitamin 25(OH)D: 14.6 (range 30-100) ngr/mL, Parathyroid hormone (PTH): 0.6 (range 1.6-6.9) pmol/L, and PTHrP < 8.5 pgl/mL (<13). The examination of 24

Table 2. Case reports of adults patients with non-T acute lymphoblastic leukaemia, hypercalcemia and osteolysis.

Author/Year	Age/Sex	Index Disease	Features	Outcome	Possible Mechanism
Stein/1988[12]	50/Male	Common ALL	Hypercalcemia and painful ribs	Remission	N/A
Maruyama/1992[13]	37/Female	ALL	Hypercalcemia, lumbago, nausea and vomiting	Complete remission	PTHrP
Ogihara/1995[14]	62/Female	ALL, L1	Bone pain, hypercalcemia	Remission	PTHrP
Fukasawa/2001[15]	53/Female	early B-cell ALL	Osteolysis and hypercalcemia	Remission	TNF-alpha, IL-6, and soluble IL-2 receptor
Mori/2007[16]	70/Male	ALL, L2	Left ankle pain, multiple osteolytic lesions, hypercalcemia	Death of acute pneumonia and gastrointestinal bleeding	PTHrP TNF-alpha, and IL-6
Verma/2013[17]	27/Female	Pre-B ALL	Paraparesis and multiple osteolytic lesions in skull	Remission	N/A

TNF-a: tumor necrosis factor alpha, ALL: acute lymphoblastic leukaemia, pre-B ALL: precursor B acute lymphoblastic leukaemia, PTHrP: parathyroid hormone related protein, N/A: Not available,

hours urine collection revealed urine calcium 1176.6 mg and urine phosphorus 1139.6 mg. Cerebrospinal fluid infiltration was absent.

The bone marrow aspiration indicated 9% blastic population positive for CD19 (100%), CD10 (45%), iCD22 (40%), terminal deoxynucleotidyl transferase (TdT) (68%), iCD79a (62%), CD34 (100%), CD38 (68%), HLA DR, and additional antigens CD11b (12%), CD13 (15%) and intracellular myeloperoxidase (iMPO) (28%) that are normally associated with myeloid lineage. Cytogenetic analysis revealed 46,XY,dup(1)(q21q32),del(8)(p22)[12]/46,XY[8] which was consisted with mixed phenotype acute leukemia (Table1). Trephine bone marrow biopsy was not performed. Computed tomography and magnetic resonance imaging showed multiple diffused well-defined osteolytic lesions in all lumbar vertebrae, sacrum, ilium and both femora (Figure 1).

After reviewing laboratory, radiological and clinical findings, we diagnosed our patient as having relapse of mixed phenotype acute leukemia with multiple osteolytic lesions, hypercalcemia and mild renal function deterioration. The patient had neither lymphadenopathy nor organomegaly, but only severe lumbar pain. Thus, FLAG-IDA (fludarabine, aracytin, G-CSF, idarubicin) rescue therapy due to relapse and the phenotypical conversion of ALL, and hydration plus furosemide, corticoids and bisphosphonates for hypercalcemia, were administered. After six days, the calcium level was normalized and accompanied with amelioration of his renal function and alleviation of the painful symptoms. One month after the first cycle of FLAG-IDA, he exhibited a second event of hypercalcemia and relapse of ALL with the same features as previously described, and he received the same treatment (second cycle of FLAG-IDA) (Figure 2). Nonetheless, his general condition was deteriorated by developing bilateral meralgia paresthetica and he died soon after the episode due to severe sepsis.

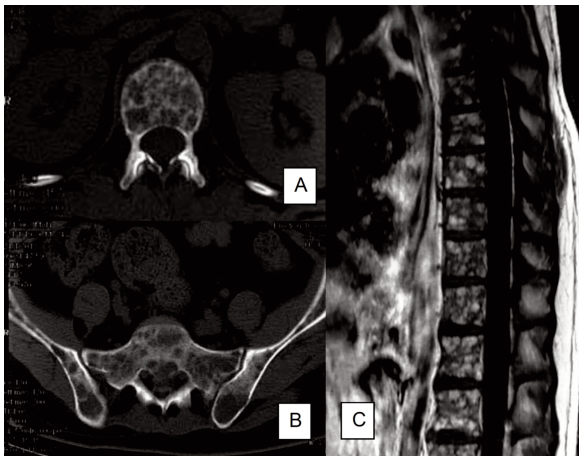

Figure 1. Multiple diffused well-defined osteolytic lesions in all lumbar vertebrae, sacrum and ilium on computed tomography (A,B) and magnetic resonance imaging (C).

Discussion

Osteopathy, including bone pain and pathologic fracture, is certainly one of the most common initial symptoms of ALL mainly in children and adolescents, but multiple osteolytic lesions are limited[2,4]. Generally, hypercalcemia is a common complication of adult patients with

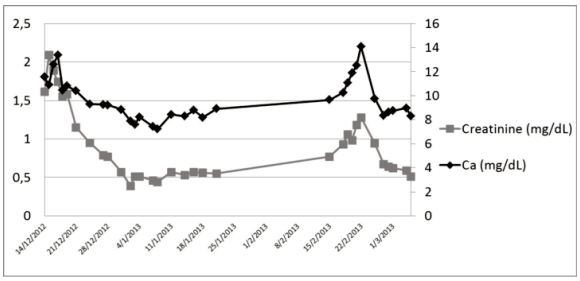

Figure 2. Calcium and serum creatinine levels of the 24-year-old male patient, with relapsed precursor B acute lymphoblastic leukaemia, during his hospitalization.

cancer and two possible mechanisms for the elevated serum calcium levels have been suggested.

The first mechanism is local osteolytic hypercalcemia due to osteolytic skeletal metastases and possible cytokine involvement. In multiple myeloma or adult T cell leukemia/lymphoma, the primary mechanism of hypercalcemia is increased osteoclastic bone resorption by tumor cells (leukemic infiltration) in combination with local bleeding and osteonecrosis of the adjacent bone structures[5].

The second suggested mechanism in hematological malignancy is the paraneoplastic production of humoral factors, mainly PTHrP[6], vitamin-D-like sterols[7], prostaglandin E2[8], TNF-α[9], and IL-6[10]. In the reported case, serum PTH and $1,25(OH)_2D$ were below the normal ranges due to hypercalcemia but also PTHrP level was normal. Cytokines were not determined because of the aforementioned reports, and the lack of a specific and reliable bioassay for their detection. Therefore, the cause of hypercalcemia in our case remains unexplained.

However, cause and result of hypercalcemia could be renal failure. In hypercalcemia in malignancy, hypercalciuria is caused by increased calcium in the glomerular filtrate, although renal calcium's reabsorption is increased. Since kidney is the major excretory organ for calcium, it could inappropriately retain the large calcium load, which results from accelerated bone resorption[11]. Our patient developed hypercalcemia accompanied by mild hyperphosphatemia. A possible mechanism of induced renal failure could be the deposition of calcium in the kidney secondary, because of an increase in the calcium-phosphorus product.

Besides hypercalcemia, cytogenetic abnormalities and expression of myeloid antigens (CD11b, CD13, and iMPO) by blast cells were evident at relapse of pre B-ALL. This phenotypical conversion from pre B-ALL to leukemia with myeloid features is known as a lineage switch. This condition is now defined as mixed phenotype acute leukemia (MPAL), according to WHO Classification of Tumors of Hematopoietic and Lymphoid Tissues, 2008[12]. Very early hemopoietic progenitor cells are possibly involved in the origin of MPAL with the potential to undergo either on myeloid or on lymphoid differentiation. MPAL is more frequent in adults. Although, the prognosis of ALL with multiple osteolytic lesions or hypercalcemia alone is debatable, when combined with adulthood, aberrant cytogenetics, and MPAL it is undoubtedly poor.

The clinical features of the reported patient, such as multiple osteolytic lesions with hypercalcemia and a normal white blood cell count without lymphoblasts in the peripheral blood, are very similar to other reported cases[2,8]. Case reports of children and adolescents presenting with bone pain and osteolytic lesions are plenty but there are only few adult patients with osteolytic lesions and hypercalcemia in B acute lymphoblastic leukemia[12-15] (Table 2). In conclusion, to our knowledge, this is a rare case report of pre-B ALL in early adulthood with hypercalcemia and multiple osteolytic lesions, highlighting a combination of unusual manifestations in relapsed ALL and the aggressive evolution of the disease despite the long-term remission, indicating a possible feature of poor prognosis.

Conflict of interest

Authors declare no conflict of interest.

Acknowledgements

Authors express their special acknowledgments to Vasiliki Tsavdaridou, Evdoxia Gounari, Elissavet Chrisoulidou, Angeliki Giannouli, and Anna Kalogera-Foutzila for their helpful advices.

References

1. Bassan R, Gatta G, Tondini C, Willemze R. Adult acute lymphoblastic leukaemia. Crit Rev Oncol Hematol. 2004; 50: 223-261.
2. Soni PN. Hypercalcaemia and multiple osteolytic lesions in childhood acute lymphoblastic leukaemia. Postgrad Med J. 1993; 69: 483-485.
3. Niizuma H, Fujii K, Sato A, Fujiwara I, Takeyama J, Imaizumi M. PTHrP-independent hypercalcemia with increased proinflammatory cytokines and bone resorption in two children with CD19-negative precursor B acute lymphoblastic leukemia. Pediatr Blood Cancer. 2007; 49: 990-993.
4. Margolin JF, Steuber CP, Poplack DG. Acute lymphoblastic leukemia. Pizzo PA, Poplack DG (eds). Principles and practices of pediatric oncology. Lippincott Williams & Wilkins, Philadelphia, 2002, 489-544.
5. Esbrit P. Hypercalcemia of malignancy--new insights into an old syndrome. Clin Lab. 2001; 47: 67-71.
6. Shimonodan H, Nagayama J, Nagatoshi Y, Hatanaka M, Takada A, Iguchi H, et al. Acute lymphocytic leukaemia in adolescence with multiple osteolytic lesions and hypercalcaemia mediated by lymphoblast-producing parathyroid hormone-related peptide: a case report and review of the literature. Pediatr Blood Cancer. 2005; 45: 333-339.
7. Jacobson JO, Bringhurst FR, Harris NL, Weitzman SA, Aisenberg AC. Humoral hypercalcemia in Hodgkin's disease. Clinical and laboratory evaluation. Cancer. 1989; 63: 917-923.
8. Lee YH, Lim YJ, Bae JJ, Kim JY, Shin JH. Hypercalcemia and Extensive Osteolytic Lesion with Increased Plasma Prostaglandin E2 Level in a Child with Acute Lymphoblastic Leukemia. Korean J Hematol. 2007; 42: 433-438.
9. Antunovic P, Marisavljevic D, Kraguljac N, Jelusic V. Severe hypercalcemia and extensive osteolytic lesions in an adult patient with T cell acute lymphoblastic leukaemia. Med Oncol. 1998;15: 58-60.
10. Tamura T, Udagawa N, Takahashi N, Miyaura C, Tanaka S, Yamada Y, et al. Soluble interleukin-6 receptor triggers osteoclast formation by interleukin 6. Proc Natl Acad Sci USA. 1993; 90: 11924-11928.
11. Swerdlow SH, Campo E, Harris NL, Jaffe ES, Pileri SA, Stein H, et al. World Health Organization Classification of Tumours. Pathology and Genetics of Tumours of Haematopoietic and Lymphoid Tissues. IARC Press, Lyon, France 2008, 150-155.
12. Stein A, Boughton BJ. Common acute lymphoblastic leukaemia in an adult with hypercalcemia and lytic bone lesions. Br J Haematol 1988; 70: 503.
13. Maruyama H, Kawano K, Uno H, Matsuoka H, Yamashita R, Tamaki N, et al. [Acute lymphocytic leukemia (L1) preceded by hypercalcemia]. Rinsho Ketsueki. 1992; 33: 514-519.
14. Ogihara T, Kikuchi Y, Imai Y, Ohsaka A, Isaka M, Oka Y. [Acute lymphoblastic leukemia accompanied by severe hypercalcemia; successful treatment with bisphosphonate]. Rinsho Ketsueki. 1995; 36: 29-34.
15. Fukasawa H, Kato A, Fujigaki Y, Yonemura K, Furuya R, Hishida A. Hypercalcemia in a patient with B-cell acute lymphoblastic leukemia: a role of proinflammatory cytokine. Am J Med Sci. 2001; 322: 109-112.
16. Mori A, Toyoshima N, Saito M, Oka T, Irie T, Morioka M. [Hypercalcemia and multiple osteolytic lesions associated with proinflammatory cytokines in a patient with acute lymphoblastic leukemia]. Rinsho Ketsueki. 2007; 48: 559-564.
17. Verma SP, Dubashi B, Basu D, Dutta TK, Kar R. A rare case of adult acute lymphoblastic leukemia presenting with paraparesis and multiple osteolytic lesions. Indian J Hematol Blood Transfus. 2014; 30: 24-26.