

Cystic lymphangioma of the inguinal and scrotal regions in childhood - report of three cases

Patoulas I¹, Prodromou K¹, Feidantsis Th¹, Kallergis I², Koutsoumis G¹

¹1st Pediatric Surgery Department, Aristotle University, "G. Gennimatas" Hospital

²Urology Clinic, "Panagia" Hospital
Thessaloniki, Greece

Abstract

Background: Cystic lymphangiomas are congenital lymphatic malformations that most commonly develop in the neck, axilla, mediastinum and retroperitoneum. Inguinal and scrotal lymphangiomas are extremely rare.

Cases report: We present the cases of three children with cystic lymphangiomas that were treated in our department during a two year period. The patients were all boys, aged 3.5, 9 and 13 years, and the location of the cystic lymphangioma was the scrotum, the inguinal region and the epididymis respectively. Clinical examination and ultrasonography described the lesions as cystic. Surgical excision of the lesions with a testis-sparing approach was performed in all three cases and histopathology set the diagnosis of cystic lymphangiomas. Complementary imaging of the regions adjacent to the excised lesions, excluded any extension or co-existing lesions. Post-operative period was uneventful and during a follow-up period of six months all patients were well with no signs of recurrence.

Conclusions: Scrotal and inguinal cystic lymphangiomas are treated with surgical excision with care to preserve the intra-scrotal structures and the structures of the inguinal canal. Complete excision is necessary to prevent recurrence. Complementary imaging of the adjacent regions is necessary to identify any possible extension or co-existing lesions. Hippokratia 2014; 18 (1):88-91.

Keywords: Cystic lymphangioma, inguinal region, scrotum, epididymis, childhood, ultrasonography, complementary imaging

Corresponding author: Katerina Prodromou, Pediatric surgeon, 92 Pileas street, Thessaloniki 54454, Greece, tel: +302310922195, +306947439510, fax: +302310992529, e-mail: prodromou.katerina@gmail.com

Introduction

Lymphangiomas are congenital lymphatic malformations which may develop in the head and neck (75%), axilla (20%), mediastinum, mesentery, retroperitoneum and more rarely in the liver, spleen, pancreas, bones, kidneys, intestine, scrotum, bladder, inguinal regions etc (5%)¹. Even though lymphangiomas are traditionally classified as capillary, cavernous and cystic, this classification cannot be generally applied as commonly all types co-exist in the same lesion².

We report three rare cases of young children with scrotal, epididymal and inguinal lymphangioma respectively, in order to emphasize on the difficulties of the pre-operative diagnosis of such lesions due to their varying appearance. These children were treated in the First Department of Pediatric Surgery of the Aristotle University of Thessaloniki, from September 2011 to June 2012.

Case report 1

A 3.5 year-old boy with a past history of leukodystrophy and diffuse vascular malformations of the face, trunk and lower extremities presented with a painless,

soft mass in the right inguinal region expanding to the right hemi-scrotum, posterior to the testicle. The mass was first noticed by the patient's parents 2 days prior to presentation. Initially the lesion was considered to be an inguinal hernia and was subjected to several unsuccessful attempts for reduction. There were no signs of hernia strangulation and both testicles were of normal texture and at the proper position. Ultrasonography showed a lesion in the right hemi-scrotum, with cystic compounds, which coiled around the spermatic cord (Figure 1).

During his third day of hospital stay, the patient developed a spontaneous hematoma at the right hemi-scrotum, which was attributed to the previous repeated physical examinations that possibly caused minor injury and hemorrhage within the cystic lesion. Without having been precisely diagnosed and in absence of any signs of damage to the testicle, the young patient was discharged on the 4th day so as to allow for the hematoma to settle. He was re-examined a month later and the inguinal mass had completely resolved and three small, firm, palpable lesions were noticed in the right hemi-scrotum, parallel to the spermatic cord. Ultrasonography demonstrated three lesions in the upper right

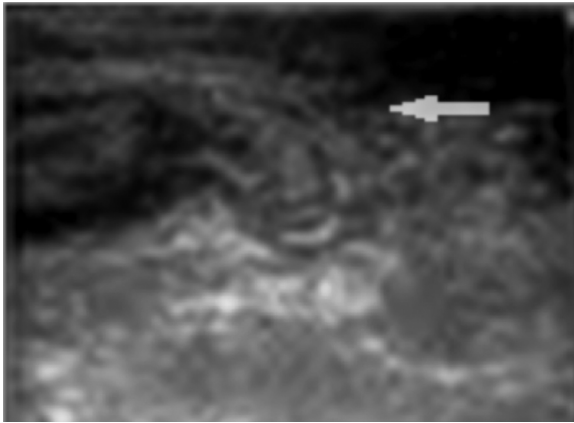


Figure 1: Ultrasonographic image demonstrating a lesion in the right hemi-scrotum, with cystic compounds, which coils around the spermatic cord (arrow).

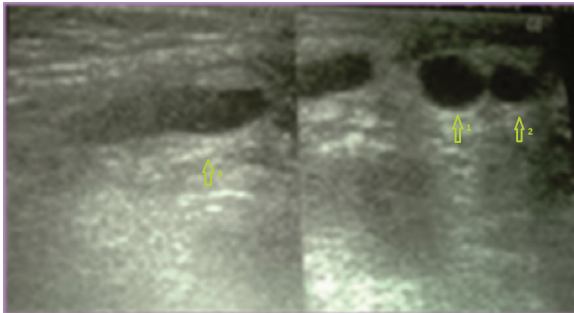


Figure 2: Ultrasonographic image demonstrating three lesions in the upper right quadrant of the right hemi-scrotum measuring 5 mm (arrow 1), 7 mm (arrow 2) and 20 mm (arrow 3) in their greatest dimensions.

quadrant of the right hemi-scrotum measuring 5, 7 and 20 mm in their greatest dimensions (Figure 2). Surgical exploration was performed via a right inguinal incision and the three lesions were identified and excised. No pathology of the processus vaginalis, testis or epididymis was noticed. Macroscopic examination of the specimens showed three soft, fluctuant lesions with cystic spaces filled with fluid. Histopathologic examination showed multiple dilated spaces lined by a single layer of epithelium and lymphocytes; occasional lumens contained small amounts of flocculent material and some red blood cells. Lymphoid follicles and loose connective tissue were found in the intervening stroma. The histopathologic diagnosis was that of cystic lymphangioma.

One month after the operation, an ultrasonographic examination of the patient's contralateral hemi-scrotum, inguinal region, perineum and pelvis was performed, that showed no signs of co-existing cystic lymphangiomas or extension of the primary lesion to the above-mentioned areas. During a follow-up period of 6 months, no clinical or ultrasonographic signs of recurrence were noticed.

Case report 2

A 13-year-old boy presented with a painless mass at the right hemi-scrotum which he discovered through self-examination. Ultrasonography demonstrated a multi-cystic lesion attached to the right epididymis (raising the possibility of a cystic

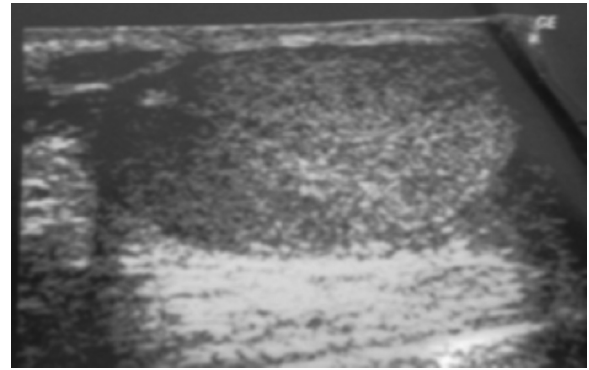


Figure 3: Scrotal ultrasound image showing a multi-cystic lesion attached to the right epididymis.

lymphangioma) and a small hydrocele (Figure 3). Scheduled surgery through scrotal approach was performed. Following the incision of its tunics, the testicle was retracted into the surgical field and a lobed cystic lesion was identified attached to the head and body of the epididymis (Figure 4). The thin integument covering the lesion was carefully dissected and the lesion was excised in toto. Macroscopic examination of the specimen showed a soft, well-circumscribed mass with irregular cystic spaces filled with whitish fluid. Histopathologic examination showed multiple dilated lymph channels with a thin wall and a lining of flattened endothelial cells (Figure 5). One month after the operation the patient underwent an ultrasonographic examination of the left hemi-scrotum, left inguinal region, perineum and pelvis with no abnormal findings. During a six months' follow-up period, there were no signs of relapse of the lymphangioma.

Case report 3

A 9-year-old boy presented with a 65 mm long mass in the left inguinal region. Although this mass was first noticed by his parents during infancy, they were not alarmed by its presence. The lesion was reported as a "painless, soft, small" mass that remained stable in size until the age of 7 and then progressively enlarged. A cystic lymphangioma was suspected. Ultrasonography showed a subcutaneous cystic lesion containing echogenic material, divided with septa into 3 isolated compartments

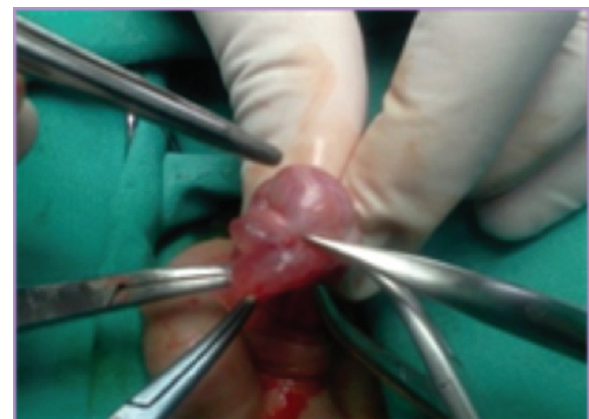

Figure 4: Intraoperative image of the surgical finding of a lobed cyst attached to the head and body of the epididymis.

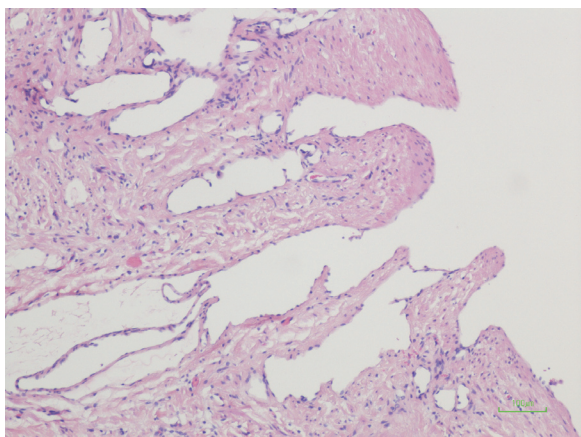


Figure 5: Histopathology image (Hematoxylin & Eosin, x 400) demonstrating the thin wall of the lymphatic channels, lined by flattened endothelial cells.

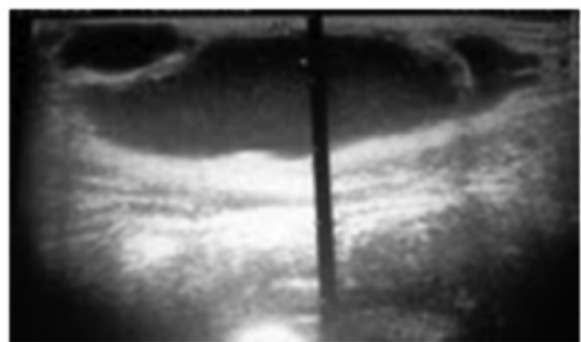


Figure 6: Ultrasonographic image of the subcutaneous cystic lesion which is septated into 3 isolated compartments, containing echogenic material.

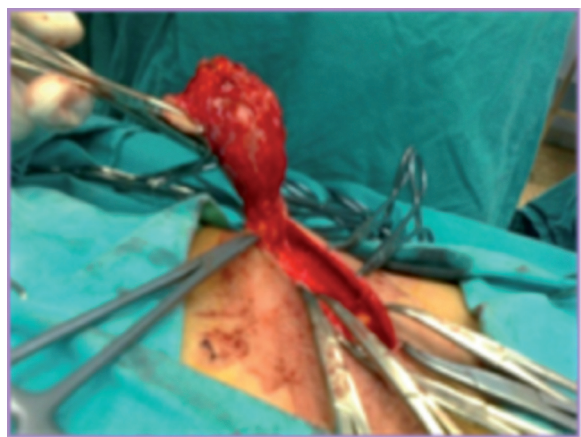


Figure 7: Intraoperative image demonstrating the dissection of the lesion from the subcutaneous tissue.

(Figure 6). Surgical exploration through an inguinal incision was performed. After careful dissection from the adjacent subcutaneous tissue, with preservation of the anterior wall of the inguinal canal, the lesion was completely excised (Figure 7). Histopathologic examination corroborated the diagnosis of a cystic lymphangioma. The specimen consisted of a flattened, rubbery mass of soft tissue measuring 6.5 cm in its greatest dimension. On the section, the tissue was spongy and extruded mini-

mal fluid. Microscopically, the tissue comprised numerous cavernous spaces lined by a single layer endothelium. The intervening stroma consisted of nondescript loose connective tissue.

Thirty days after surgery, an ultrasonographic examination of the patient's right hemi-scrotum, right inguinal region, perineum and pelvis was performed. There were no findings of co-existing lesions or extension of the cystic lymphangioma.

Discussion

Cystic lymphangiomas are congenital benign tumors of unknown etiology. The majority of lymphangiomas (90%) develop during the first two years of life and 50% are present at birth³. They are usually multi-cystic lesions lined by one or two layers of cells with various amounts of fibrous stroma separating the cysts into cavities⁴.

A cystic lymphangioma usually presents as a painless mass that progressively enlarges over time⁵. Occasionally it presents with an acute onset of pain and sudden rapid enlargement⁵. This occurs after a hemorrhage within the cyst (spontaneous or following injury), an inflammation or a disruption of the balance between lymphatic production and drainage⁶. In the first presented case, we assumed that the repeated physical examination of the patient was the cause of the traumatic hemorrhage within the cyst that led to the development of the hematoma in the right hemi-scrotum, thus complicating the pre-operative diagnosis of the lesion.

Inguinal and scrotal lymphangiomas are rare. Epididymal lymphangiomas are extremely rare with only 6 such cases reported in literature^{7,8}. Differential diagnosis should include other cystic lesions of these regions such as teratomas, enlargement of rete testis, intra- or extra-testicular dermoid and epidermoid cysts, hydroceles, hernias, spermatoceles and varicoceles^{3,9}. During the neonatal period and infancy, simple cysts of the testicle and granulocyte tumors should also be considered³. Cystic testicular lesions are in their majority benign. The reported incidence of testicular tumors during childhood is 0.5-1/100,000 boys mainly concerning sarcomas and germ cell tumors (yolk sac or teratomas)¹⁰.

Ultrasonography combined with Doppler examination can provide important insights, useful to the differential diagnosis and surgical approach of these lesions^{11,12}. It is helpful in confirming the cystic nature of the lesion, the existence of septa, the lobulated appearance of the thin wall, the absence of blood flow within the lesion and the extra-testicular origin of an intra-scrotal mass. In all three of our cases, ultrasonography was performed with findings similar to the aforementioned. The variety of cystic lesions of the inguinal and scrotal region, as well as the possibility of intra-cystic hemorrhage or inflammation impede the precise pre-operative diagnosis of a cystic lymphangioma^{2,3,5,13}. In the reported second and third cases, clinical history, physical examination and ultrasonography raised the suspicion of cystic lymphangiomas. However, histopathologic examination set the final

diagnosis.

During the follow-up period, ultrasonographic examination of the adjacent regions was performed in all three reported cases thus excluding the extension of the lymphangiomas as well as co-existing lesions. The contralateral hemi-scrotum or inguinal region, the perineum and the pelvis should always be investigated by ultrasonography^{4-6,13,14}. In need of more precise information or proof of possible extension to the adjacent structures, a computed tomography scan or a magnetic resonance imaging can be performed⁵.

Recurrence of cystic lymphangiomas is a frequent complication when complete excision is not achieved^{1,3-5}. During a follow-up period of six months our patients showed no signs of recurrence.

Scrotal and inguinal cystic lymphangiomas are treated with surgical excision with care to preserve the intra-scrotal structures and the structures of the inguinal canal. Complete excision is necessary to prevent recurrence.

Conflict of interest

None declared.

References

1. Arzoz Fàbregas M, Ibarz Servio LL, Areal Calama J, González Satué C, Ruiz Domínguez J, Saladié Roig JM. [Cystic lymphangioma. Our experience]. *Actas Urol Esp.* 2006; 30: 723-727.
2. Al-Jabri T, Gruener AM. A rare case of lymphangioma of the scrotum in a 3 year old boy: a case report. *Cases J.* 2009; 2: 183.
3. Mulcahy JJ, Schileru G, Donmezer M, Bhatena D. Lymphangioma of scrotum. *Urology.* 1979; 14: 64-65.
4. Liniger B, Fleischmann A, Zachariou Z. Benign cystic lesions in the testis of children. *J Pediatr Urol.* 2012; 8: 226-233.
5. Weidman ER, Cerdron M, Schned AR, Harris RD. Scrotal lymphangioma: an uncommon cause for a scrotal mass. *J Ultrasound Med.* 2002; 21: 669-672.
6. MacMillan RW, MacDonald BR, Alpern HD. Scrotal lymphangioma. *Urology* 1984; 23: 79-80.
7. Kok KY, Telesinghe PU. Lymphangioma of the epididymis. *Singapore Med J.* 2002; 43: 249-250.
8. Pai KK, Roy D. Lymphangioma of epididymis: An extremely rare cause of scrotal swelling. *Ind J Urol.* 2006; 22: 275-276.
9. Jamal YS, Abdel-Halim AR, Moshref SS, Kurdi MO, Sandugji HI. Cystic lymphangiomas of spermatic cord: A case report and literature review. *JKAU Med Sci.* 2009; 16: 103-111.
10. Taskinen S, Fagerholm R, Aronniemi J, Rintala R, Taskinen M. Testicular tumors in children and adolescents. *J Pediatr Urol.* 2008; 4:134-137.
11. Munden MM, Trauwein LM. Scrotal pathology in pediatrics with sonographic imaging. *Curr Probl Diagn Radiol.* 2000; 29: 185-205.
12. Dogra VS, Gottlieb RH, Oka M, Rubens DJ. Sonography of the scrotum. *Radiology.* 2003; 227: 18-36.
13. Koizumi S, Hayashida H, Hamaguchi A, Konishi T, Pak KI, Okada Y, et al. [Hemo-lymphangioma of the scrotum: a case report]. *Hinyokika Kiyo.* 1997; 43: 307-309.
14. Liolios N, Anagnostopoulos D, Sfougaris D, Valioulis I, Kas-selas V, Malliaropoulos N: Abdominoscrotal hydrocele. *Eur J Pediatr Surg.* 1997; 7: 371-372.