

Primary Rectal Malignant Melanoma-Case Report

Gavriilidis P¹, Moula E², Nikolaidou A²

¹Department of Surgical Oncology

²Department of Pathology

Theageneio Anticancer Hospital, Thessaloniki, Greece

Abstract

Introduction: Primary malignant melanoma that arises from the true anatomic rectal mucosa is extremely rare.

Case report: An endoscopic investigation of a 79-year-old woman with long history of tenesmus and rectal bleeding revealed posterior fleshy mass 4.5 cm from the anal verge. Biopsies demonstrated malignant melanoma. She underwent abdominoperineal resection and is doing well one year after the operation.

Conclusion: Owing to its rarity and histologic variability, misdiagnosis as lymphoma, carcinoma or sarcoma is common. Hippokratia 2013; 17 (4): 380-381.

Key words: Rectal melanoma, anorectal malignancies, malignant melanoma

Corresponding Author: Dr Paschalis Gavriilidis, 2 A Simeonidi STR, 54641 Thessaloniki, Greece, tel: +306977826253, e-mail: pgav7461@yahoo.com

Introduction

Primary Rectal malignant melanoma is extremely rare. For this reason, when malignant melanoma is found in the rectum, it is important to rule out a metastatic implant or an extension from a primary anal lesion as the cause of the rectal lesion¹⁻⁴.

Case Presentation

A 79-year-old Caucasian woman referred to our anticancer hospital with a long history of tenesmus and recent rectal bleeding. There was no significant past medical history apart from hypertension. Rectal examination revealed a posterior fleshy mass situated 4.5cm from the anal verge and just above the anorectal angle. There was no clinical involvement of the inguinal nodes. Biopsies demonstrated malignant melanoma. Completion colonoscopy was otherwise unremarkable. Computed tomography (CT) of the thorax, abdomen and pelvis and magnetic resonance imaging (MRI) of the pelvis showed well preserved anorectal fat planes and no evidence of metastasis. Dermatological and ophthalmological examinations revealed no evidence of a cutaneous or an ocular primary lesion. Her case was discussed at the melanoma and colorectal multi-disciplinary meetings. The patient underwent abdominoperineal resection (APR). She made an uncomplicated recovery and was discharged on the 9th postoperative day. Immunohistochemical confirmation was obtained with cellular positivity for S 100 and melan-A antigens. At pathological report 10 out of 28 lymph nodes were involved. The distance between the tumour and the anal verge was 4.5cm and its diameter was 4.7cm (Figure 1).

Postoperative adjuvant chemotherapy was not performed because of advanced age.

She is doing well one year after the operation and fol-

lowed-up every three months at melanoma and colorectal outpatient clinics.

Discussion

As primary rectal melanoma is defined any melanoma, when it occurs in the rectum above the dentate line⁵.

The incidence rate has been reported to be 0.1%-4.6% of all anorectal malignant neoplasias and 0.4%-3% of all melanomas⁶. It usually appears in elder patients with clear female predominance, varying from 54%-76%⁵.

The most common symptoms at presentation are tenesmus, rectal bleeding, constipation, decreased stool calibre, weight loss and palpable inguinal mass¹⁻³. The clinical diagnosis may be incorrect in 80% of all cases⁷. At the time of diagnosis up to 60% of patients have metastases⁶.

Histopathological misdiagnosis is not uncommon, especially in amelanotic cases with unusual morphologic features that can be mistaken for lymphoma, carcinoma, and /or sarcoma⁸⁻¹⁰. Anti-S-100 protein, Human melanoma black (HMB-45) and antibodies to melan A are the most common "melanocyte specific" stains used in the diagnosis of malignant melanoma^{9,10} (figures 2 and 3).

Due to its relative rarity, the treatment of anorectal melanoma is controversial; while it is clear that surgical resection is favoured the extent of surgery has been called into question.

In a retrospective study at the Memorial Sloan Kettering Cancer Centre the authors showed a paradigm shift from APR to wide local excision (WLE)¹¹. They reported that, between 1984 and 1996, 15 of 21 (71%) patients underwent an APR. However, from 1997 to 2003, 21 of 25 (84%) patients underwent a WLE. No differences were seen in patterns of relapse between patients treated with an APR or a WLE: 5 of 19 (26%) patients in the APR

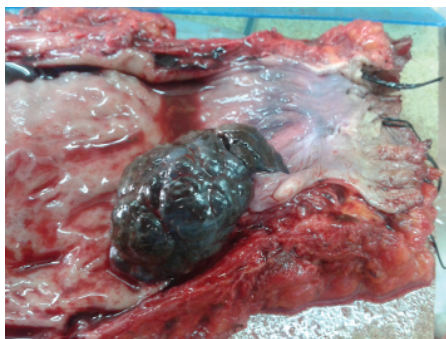


Figure 1: Large lobulated fleshy mass situated 4.5 cm from the anal verge, abutting the anorectal junction.

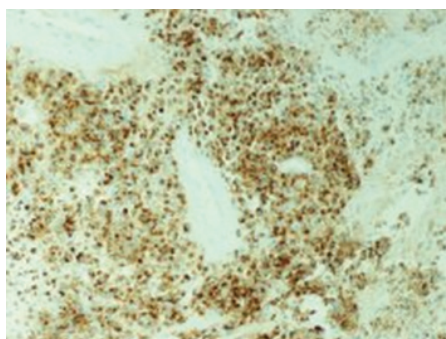


Figure 2: Intense cytoplasmic and nuclear staining of the tumour for HMB-45 (HMB-45, x200).

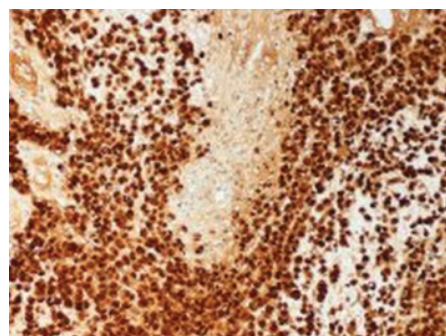


Figure 3: Diffuse and intense cytoplasmic and nuclear staining of the tumour cells for S-100 protein (S100, x200).

group and 7 of 27 (26%) in the WLE group developed local recurrence¹¹. Survival was similar in both groups 32% and 35% respectively. In a review that included 14 series has been reported that there is no stage specific survival advantage for the APR¹².

Another lingering question in the treatment strategy of anorectal melanoma (ARM) involves the approach to nodal diseases. The presence of regional lymph node metastases has not been shown to affect recurrence patterns⁶.

No series large enough has been reported to draw conclusions on the effect of the sentinel lymph node (SLN) biopsy on survival or recurrence; based on these findings some authors suggest no use of the SLNB^{13,14}.

ARM is relatively radiation insensitive tumour, but recently anecdotal responses to treatment have been reported¹⁵.

There are also individual case reports of successful palliation with intratumoral injections of interferon-beta in combination with chemotherapy in advanced case¹⁶.

The reported 5-year overall survival is 6%-15% of patients after surgery^{6,11}.

Conclusions

Patients are usually misdiagnosed as having haemorrhoids due to nonspecific symptoms of anal pain, small anorectal mass, discharge and or itching. Clinicians should suspect (ARM) in cases presenting with the above symptoms combined with tenesmus and rectal bleeding.

Conflict of Interest

Authors declare no conflict of interest.

References

- Hazzan D, Reissman P, Halak M, Resnick MB, Lotem M, Shiloni E. Primary rectal malignant melanoma: report of two cases. *Tech Coloproctol.* 2001; 5: 51-54.
- Nicholson AG, Cox PM, Marks CG, Cook MG. Primary malignant melanoma of the rectum. *Histopathology.* 1993; 22: 261-264.
- Nozoe T, Anai H. Amelanotic malignant melanoma of the rectum: report of a case. *Surg Today* 2001; 31: 527-529.
- Werdin C, Limas C, Knodell RG. Primary malignant melanoma of the rectum. Evidence for origination from rectal mucosal melanocytes. *Cancer.* 1988; 61: 1364-1370.
- Yap LB, Neary PA. A comparison of wide local excision with abdominoperineal resection in anorectal melanoma. *Melanoma Res.* 2004; 14: 147-150.
- Thibault C, Sagar P, Nivatongs S, Ilstrup DM, Wolff BE. Anorectal melanoma--an incurable disease? *Dis Colon Rectum.* 1997; 40: 661-668.
- Das G, Gupta S, Shukla PJ, Jagannath P. Anorectal melanoma: a large clinicopathological study from India. *Int Surg.* 2003; 88: 21-24.
- Banerjee SS, Harris M. Morphological and immunophenotypic variation in malignant melanoma. *Histopathology.* 2000; 36: 387-402.
- Gatter KC, Ralfkiaer E, Skinner J, Brown D, Heryet A, Pulford KA, et al. An immunocytochemical study of malignant melanoma and its differential diagnosis from other malignant tumours. *J Clin Pathol.* 1985; 38: 1353-1357.
- Nakhleh RE, Wick MR, Rocamora A, Swanson PE, Dehner LP. Morphologic diversity in malignant melanomas. *Am J Clin Pathol.* 1990; 93: 731-740.
- Yeh JJ, Shia J, Hwu WJ, Busam KJ, Paty PB, Guillem JG, et al. The role of abdominoperineal resection as surgical therapy for anorectal melanoma. *Ann Surg.* 2006; 244: 1012-17.
- Droesch JT, Flum DR, Mann GN. Wide local excision or abdominoperineal resection as the initial treatment for anorectal melanoma? *Am J Surg* 2005; 189: 446-449.
- Mariolis-Sapsakos T, Malamitsi J, Yakoumakis E, Orfanos F. Is sentinel node mapping useful in anorectal melanoma? *Hell J Nucl Med.* 2008; 11: 39-42.
- Gavriilidis P. Is Sentinel lymph node biopsy profitable in melanoma patients? *Hippokratia.* 2013; 17: 288.
- Moozar KL, Wong CS, Couture J. Anorectal malignant melanoma: treatment with surgery or radiation therapy, or both. *Can J Surg.* 2003; 46: 345-349.
- Ulmer A, Metzger S, Fierlbeck G. Successful palliation of stenosing anorectal melanoma by intratumoral injections with natural interferon-beta. *Melanoma Res.* 2002; 12: 395-398.