CASE REPORT

Brugada-like ECG pattern due to giant mediastinal lipoma

Asteriou C[1], Lazopoulos A[1], Giannoulis N[1], Kalafatis I[2], Barbetakis N[1]

[1]Thoracic Surgery Department
[2]Cardiology Department
Theagenio Cancer Hospital, Thessaloniki, Greece

Abstract
A case of a 33-year-old female who presented with mild dyspnea and palpitations is presented. Diagnostic investigation was consistent with a giant intrathoracic mass filling the right thoracic cavity and an abnormal electrocardiogram (Brugada-like pattern). The patient underwent surgical removal of the mass (benign lipoma) with a normal postoperative ECG pattern. Hippokratia 2013; 17 (4): 368-369.

Keywords: Arrhythmia, lipoma, mediastinum

Corresponding author: Nikolaos Barbetakis, MD, PhD, Thoracic Surgery Department, Theagenio Cancer Hospital, 2 Alexandrou Simeonidi str., 54007, Thessaloniki, Greece, e-mail: nibarbet@yahoo.gr

Introduction

Mediastinal lipomas typically arise within the anterior mediastinum and represent only 1.6–2.3% of all primary mediastinal tumors[1]. Although lipoma is histologically diagnosed as a benign tumor and grows slowly, those growing and causing clinical symptoms should be considered clinically malignant and surgery is mandatory.

Description of case

A 33 year-old female was admitted with mild dyspnea and persistent palpitations. A Brugada-like ECG pattern (right bundle branch block with coved ST segment elevation in leads V1-V3, Figure 1) and a large mediastinal mass were noted. Computed tomographic scan demonstrated a well-circumscribed lesion with fat tissue attenuation (Figure 2). Complete staging was negative for metastatic disease. Thoracotomy revealed a tumor attached to the right cardiac chambers. The lesion was extending from the right lateral thoracic wall to the pericardium. Dissection from the right atrium was difficult due to strong adhesions. The tumor (20 x 14 x 7cm, 2650gr) was encapsulated by a smooth elastic surface and composed of yellowish tissue (Figure 3). Pathology confirmed the diagnosis of a benign lipoma. Postoperative period was uncomplicated with a normal ECG pattern. The more probable cause was the compression of the right ventricular outflow tract caused by the mass.

Discussion

Lipomas are almost always benign in nature and malignant degeneration is very rarely reported. Intrathoracic benign lipomas are extremely uncommon. They are fully encapsulated and very slow growing, often over many years [1]. They are usually identified by routine chest radiograph or are discovered after the patient presents with symptoms of shortness of breath with exertion or dyspnea secondary to the compression of the bronchi, vagus nerve, esophagus, or other internal structures. Other symptoms can include cough, arrhythmias, orthopnea and intermittent dysphagia[2]. Differential diagnosis of mediastinal fatty masses may include benign lipomas, thymolipomas, liposarcomasand germ cell neoplasms[1,3-6].Differentiating a lipoma from a liposarcoma can be challenging in many cases, especially if it is a low-grade malignancy[2].

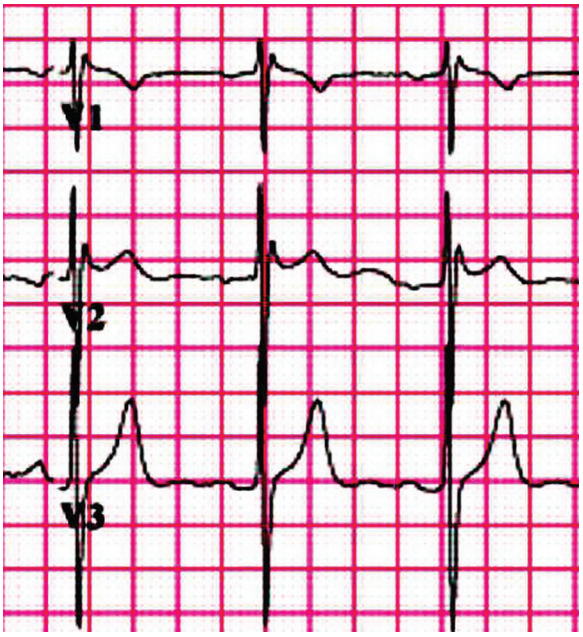

Figure 1: Brugada like ECG pattern (right bundle branch block with coved ST segment elevation in leads V1-V3).

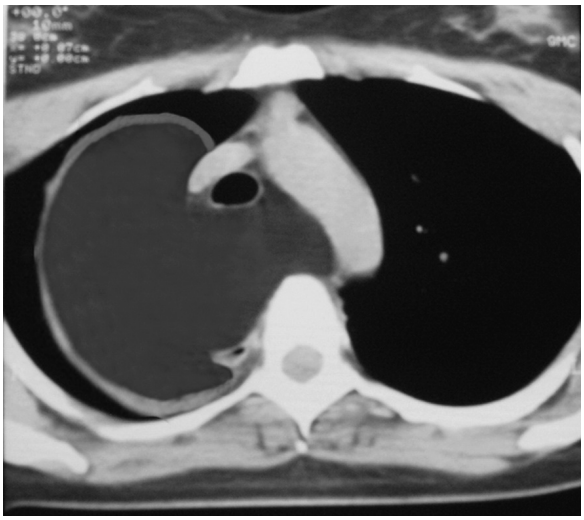

Figure 2: Computed tomography demonstrated a well-circuscrimbed intrathoracic mass with fat tissue attenuation.

Figure 3: Macroscopic appearance of the tumor.

Several causes are known to induce the right precordial ST elevation mimicking Brugada syndrome. Right ventricular outflow area is assumed to be responsible for such ECG changes. Mediastinal tumor as a cause of Brugada-like ECG pattern is reported only once in the international literature[7]. Current recommendations include complete en bloc removal of such tumors whenever possible, as this is the only definitive treatment option. Once resected, local recurrence of intrathoracic or mediastinal-lipomas is uncommon.

Conflict of interest

There is no conflict of interest with any financial organization regarding the material discussed in the manuscript.

References

1. Gaerte SC, Meyer CA, Winer-Muram HT, Tarver RD, Conces DJ Jr. Fat-containing lesions of the chest. Radiographics. 2002; 22: 61-78.
2. Hagmaier RM, Nelson GA, Daniels LJ, Riker AI. Successful removal of a giant intrathoracic lipoma: a case report and review of the literature. Cases J. 2008; 1: 87.
3. Barbetakis N, Samanidis G, Samanidou E, Kirodimos E, Kiziridou A, Bischiniotis T, et al. Primary mediastinal liposarcoma: a case report. J Med Case Rep. 2007; 1: 161.
4. Noji T, Morikawa T, Kaji M, Ohtake S, Katoh H. Successful resection of a recurrent mediastinal liposarcoma invading the pericardium: report of a case. Surg Today. 2004; 34: 450-452.
5. Juanpere S, Cañete N, Ortuño P, Martínez S, Sanchez G, Bernado L. A diagnostic approach to the mediastinal masses. Insights Imaging. 2013; 4: 29-52.
6. Ganesh Y, Yadala V, Nalini Y, Dal A, Raju AD. Huge mediastinal mass with minimal symptoms: thymolipoma. BMJ Case Rep. 2011; 2011: bcr0520102984.
7. Tarín N, Farré J, Rubio JM, Tuñón J, Castro-Dorticós J. Brugada-like electrocardiographic pattern in a patient with a mediastinal tumor. Pacing Clin Electrophysiol. 1999; 22: 1264-1266.