

Pancreatic pseudocyst in a child due to blunt abdominal trauma during a football game

Giakoustidis A, Antoniadis N, Giorgakis I, Tsoulfas G, Dimitriadis E, Giakoustidis D

Division of Transplantation, Department of Surgery, Aristotle University of Thessaloniki, Thessaloniki, Greece

Abstract

Pancreatic pseudocyst in children due to abdominal trauma is a rare entity. We report a 14-year-old boy suffering from acute pancreatitis due to blunt abdominal trauma that occurred during a football game, and resulted in a large pseudocyst formation. The child was treated conservatively for the post traumatic acute pancreatitis for 4 weeks and thereafter he was followed up for another 2 weeks. At the end of the 6 weeks after the first insult, the child underwent an open cystgastrostomy. Postoperative course was uneventful and the child was discharged on the 6th postoperative day. Hippokratia. 2012; 16 (1): 71-73

Key words: pancreatic, pseudocyst, child, cystgastrostomy

Corresponding author: Dimitrios Giakoustidis, Division of Transplantation, Department of Surgery Aristotle University of Thessaloniki, Hippokratia General Hospital, Thessaloniki, Greece, Tel: 00302310992875. Fax: +302310237911, e-mail: dgiak@auth.gr

Pancreatitis and pancreatic pseudocyst formation (PPC) due to abdominal blunt trauma in children were considered quite rare medical conditions¹. Abdominal trauma is usually secondary to handlebar bicycle injury or seatbelt injury during car accidents². The abundance and extensive use of ultrasonography (US) and computed tomography (CT) in acute and emergency cases, have increased the incidence rate of post-traumatic acute pancreatitis and pancreatic pseudocyst formation. Conservative management of PPC consists of bowel rest, nasogastric tube suction, sandostatin or octreotide, Total Parenteral Nutrition (TPN), and analgesia. When conservative management is ineffective the therapeutic options include surgical internal drainage, endoscopic drainage procedures and percutaneous catheter drainage methods.

We report a case of a blunt abdominal trauma in a 14 year old child during a football game that resulted in post-traumatic pancreatitis and formation of pancreatic pseudocyst, which was treated effectively with cystgastrostomy.

Case report

A 14-year old boy was brought to the emergency department due to blunt injury of the upper abdomen during a football game. At admission the child demonstrated pain in the upper abdomen, associated with nausea and vomiting. Physical examination revealed tenderness in the epigastric and umbilical regions. Intestinal sounds were normal.

Subsequent investigation revealed a significant rise in the white blood cell (WBC), drop of the hemoglobin, and a marked rise in serum and urine amylases respectively. Ultrasonographic (US) examination revealed a signifi-

cant amount of free fluid in the peritoneal cavity. This was confirmed by a computer tomography scan (CT), showing a vast amount of free fluid and edema and disorganization of the tail of the pancreas.

The child was admitted to the pediatric surgical department and was treated conservatively for 4 weeks with the administration of intravenous (iv) broad spectrum antibiotics and total parenteral nutrition from a central vein. The child recovered uneventfully and after the 3rd week in the hospital he started taking food orally, and the antibiotics were converted from IV to oral. Repeat CT revealed the formation of pancreatic pseudocysts in the place of the previous fluid collections. At the 4th week after admission to the hospital the patient was discharged but was followed-up closely with USG for the next two weeks. The last US revealed the unification of the previously four pseudocysts into a large one (Figure 1A). This diagnosis was in accordance with the latest CT confirming the USG diagnosis and revealing the formation of a pancreatic pseudocyst of 17cmx10cm (Figure 2). The child's condition was unremarkable apart from the fact that he was complaining of nausea and fullness during meals. In addition, serum and urine amylases were still significantly elevated compared with the normal range values.

Upon completion of a period of six weeks after the initial injury and considering that by that time the pancreatic pseudocyst would be matured, it was decided that we would proceed with the operation. A few days later under general anesthesia an upper midline incision was made, inspection of the abdomen did not reveal anything significant except for the large pancreatic pseudocyst. A gastrotomy at the anterior and posterior part of the great-

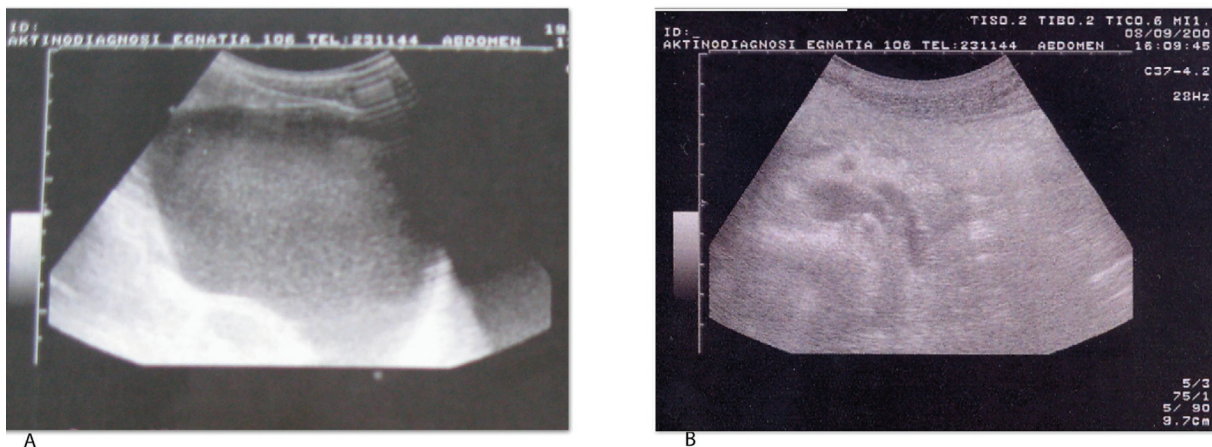


Figure 1: Preoperative (A) USG showing the PPC, and postoperative (B) USG showing the absence of the PPC

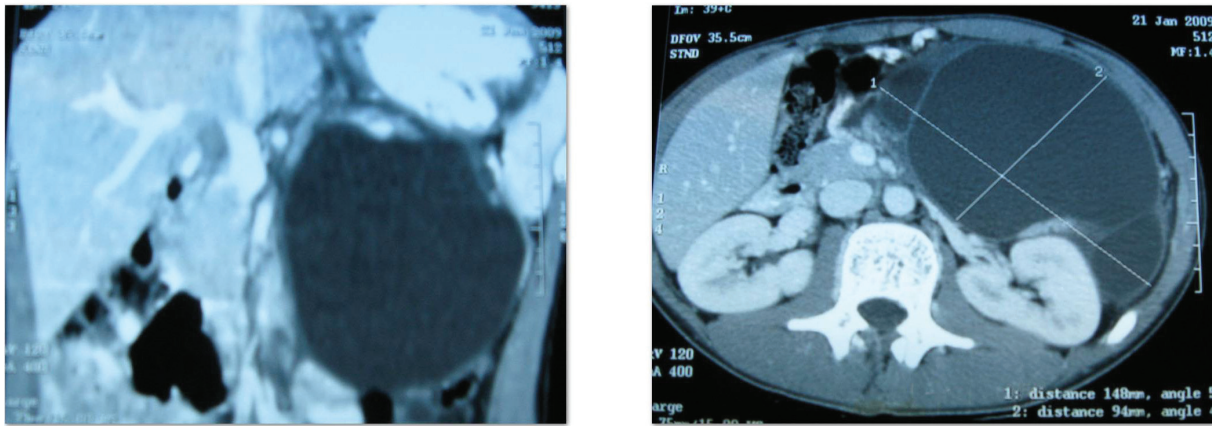


Figure 2: CT scans showing the large pancreatic pseudocyst formation

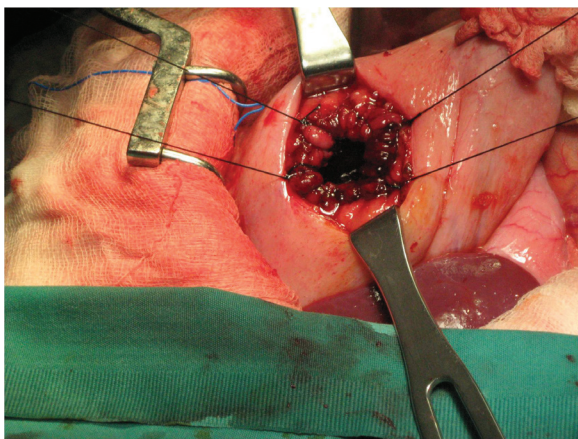


Figure 3: Intraoperative picture showing the cystgastrostomy

er curvature of the stomach was performed. Following the posterior gastrotomy, identification of the pancreatic pseudocyst's wall adjacent to stomach was performed, a window was opened and a liter of pancreatic-like fluid was aspirated. Consequently, a cystgastrostomy was performed with absorbable running suture (Figure 3). The

anterior gastrotomy was closed with a two layer absorbable running suture and no drains were placed. Postoperative course was uneventful and the child was discharged on the 6th postoperative day. Eight months after discharge a new USG (Figure 1B) revealed the absence of the pancreatic pseudocyst and otherwise normal findings. As of this writing the child has almost 2 years follow-up, and is symptom free without any complaints and in addition had gained all of the lost weight.

Discussion

Pancreatic pseudocysts in children are rare, although it is well-documented as a primary consequence of pancreatitis needing in most of the cases surgical or endoscopic intervention. The most frequent cause of PPC in children is blunt abdominal trauma with the mechanism being direct compression of the pancreas into the spine. The incidence of PPC formation following post-traumatic pancreatitis varies from 0% to 69% according to different studies, and this reflects the diversity of the severity of the pancreatic injury^{3,4}. Over the last several years non-operative management of most solid organ injuries in children has become the standard of care. Spontaneous regression of PPC is likely with conservative man-

agement with bowel rest and total parenteral nutrition, and nonoperative management is successful, particularly when the pseudocyst is less than 5 cm in diameter^{5,6}. PPC larger than 5 cm are less likely to resolve spontaneously, and may be complicated by rupture, hemorrhage, infection, or lead to gastric outlet obstruction. Options for treatment include percutaneous, endoscopic, and surgical drainage. Due to the lack of large pediatric patient series comparing the different modalities available, management is individualized and based on anecdotal data and physician and centre experience. Percutaneous drainage procedures in children have been reported, with complete resolution of traumatic pancreatic pseudocysts. This approach is favored in the setting of nonseptated, immature, or infected pseudocysts, since their usually thin wall would not be optimal for internal drainage. The success of percutaneous drainage in children is likely related to the fact that pancreatic duct disruption is uncommon but they are associated with relatively lengthy treatment sessions before complete cyst resolution is achieved^{7,8}. Endoscopic management of pancreatic pseudocysts is considered a well established technique in adults with large series of patients but in pediatric populations it has only been reported in the form of case reports and with no long-term follow up^{9,10}. Recently Sharma and Maharshi¹¹ presented a series of 9 pediatric patients with long term follow-up. All patients had immediate resolution of symptoms after endoscopic drainage with complete disappearance of the pseudocysts and there was no recurrence on follow-up so far. Due to these concerns, most surgeons advocate internal drainage as the definitive treatment of pediatric PPC, either open or laparoscopically¹².

Our case consisted of a 13 year old male child that suffered a blunt abdominal trauma during a football game that led to pancreatic injury, post traumatic pancreatitis and a massive retroperitoneal fluid collection. Initially, he was treated conservatively with bowel rest, parenteral nutrition and broad spectrum antibiotics. He was hospitalized for 4 weeks and upon improvement of his condition, he resumed feeding and antibiotics orally. During his hospital stay repeat CT scans showed the progression of the retroperitoneal collections to pancreatic pseudocysts, and the formation of 4 PPC was recognized.

The patient was discharged after the 4th week and remained in close outpatient follow up monitoring his appetite, his weight gain, possible complaints for nausea or vomiting and ultrasonography of the upper abdomen was done on a weekly basis. Upon completion of the 6th week after the initial pancreatic injury and due to an increase of nausea complaints, it was decided to proceed with an intervention. A new CT scan revealed the unification of the former 4 PPC into a large one (17cmx10cc). Open internal drainage by cystgastrostomy was our preferred approach since our laparoscopic experience with PPC in adults was minimal and in children was nil. The operation was straightforward and postoperative recovery was uneventful and the child was discharged on the 6th post operative day. After almost 2 years of postoperative

follow-up there were no symptoms of recurrence. In our approach, the significant experience we have with open internal drainage procedures prevailed over other alternatives in the final decision. The use of laparoscopy could be an excellent alternative provided significant expertise exists, even though a small number of laparoscopic cases have been published so far and most of them were case reports. Endoscopic drainage could have been an alternative treatment in our case but it was decided to proceed with the operation due to the significant size of the PPC and the possibility of finding more than one PPC.

In conclusion, PPC in children is a rare but nevertheless significant clinical entity, whose management depends on the size of the pancreatic injury, and available experience and expertise with percutaneous, endoscopic and internal drainage procedures.

References

1. Warner RL, Othersen HB, Smith CD. Traumatic pancreatitis and pseudocyst in children: current management. *J Trauma*. 1989; 29: 597-600.
2. Canty TG Sr, Weinman D. Management of major pancreatic duct injuries in children. *J Trauma*. 2001; 50: 1001-1007.
3. Benifla M, Weizman Z. Acute pancreatitis in children. *J Clin Gastroenterol*. 2003; 37: 169-172.
4. Cabrera R, Otero H, Blesa E, Jiménez C, Núñez R. Pancreatic pseudocyst: review of 22 cases. *Cir Pediatr*. 1997; 10: 49-53.
5. Teh SH, Pham TH, Lee A, Stavlo PL, Hanna AM, Moir C. Pancreatic pseudocyst in children: the impact of management strategies on outcome. *J Paediatr Surg*. 2006; 41: 1889-1893.
6. Shilyansky J, Sena LM, Kreller M, Chait P, Babyn PS, Filler RM, et al. Nonoperative management of pancreatic injuries in children. *J Pediatr Surg*. 1998; 33: 343-349.
7. Rescorla FJ, Cory D, Vane DW, Chait P, Babyn PS, Filler RM et al. Failure of percutaneous drainage in children with traumatic pancreatic pseudocyst in children. *J Pediatr Surg*. 1990; 25: 1038-1042.
8. Haluszka O, Campbell A, Horvath K. Endoscopic management of pancreatic pseudocyst in children. *Gastrointest Endosc*. 2002; 55: 128-131.
9. Kimble RM, Cohen R, Williams S. Successful endoscopic drainage of a post-traumatic pancreatic pseudocyst in a child. *J Pediatr Surg*. 1999; 34: 1518-1520.
10. Haluszka O, Campbell A, Horvath K. Endoscopic management of pancreatic pseudocyst in children. *Gastrointest Endosc*. 2002; 55: 128-131.
11. Sharma SS and Maharshi S. Endoscopic management of pancreatic pseudocyst in children—a long-term follow-up *J Pediatr Surg*. 2008; 43: 1636-1639.
12. Chowbey PK, Soni V, Sharma A, Khullar R, Baijal M, Vashista A. Laparoscopic intragastric stapled cystogastrostomy for pancreatic pseudocyst. *J Laparoendosc Adv Surg Tech A*. 2001; 11: 201-205.