

## A “sweet” hydrothorax in a child on peritoneal dialysis

Gidaris D<sup>1</sup>, Printza N<sup>1</sup>, Batzios S<sup>1</sup>, Belechri A M<sup>2</sup>, Papachristou F<sup>1</sup>

<sup>1</sup>1<sup>st</sup> Paediatric Clinic, Hippokratio General Hospital, Aristotle University of Thessaloniki, Thessaloniki, GREECE

<sup>2</sup>University Department of Nephrology, Hippokratio General Hospital, Thessaloniki, Greece

### Abstract

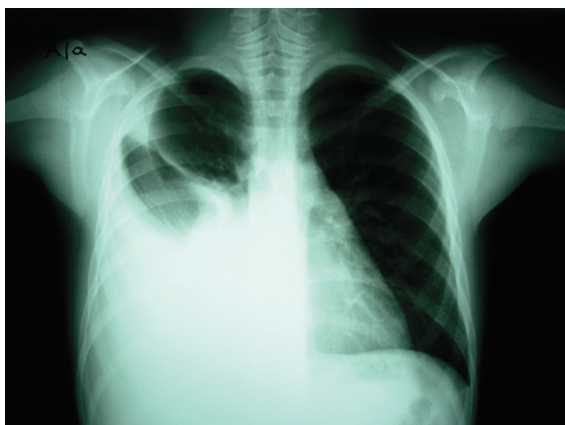
Peritoneal dialysis (PD) is an established, effective long term renal replacement treatment modality for children with end stage renal disease (ESRD). A rarely reported complication of PD in children is the development of hydrothorax<sup>1</sup>. We report the case of an 8-year-old boy that developed a right-sided pleural effusion during automated PD (APD), in order to raise awareness amongst paediatricians; we also review the diversity of clinical presentation and the available diagnostic tools, discuss theories regarding aetiology and highlight the available treatment options. Hippokratia 2011; 15 (4): 358-360

**Key words:** peritoneal dialysis, child, hydrothorax

**Corresponding author:** Dimos Gidaris, 9A, Pantazopoulou Street, Ampelokipi 56121, Thessaloniki, Greece, Tel: 00306947932194, dgie-mail:daris@doctors.prg.uk

### Case description

The patient presented is an 8-year-old boy with ESRD due to chronic tubular-interstitial nephritis who had been on APD by night for 6 months. His APD prescription was 1000mL (30mL/Kgr) volume exchange by night, without hyperosmolar solutions, with 70 minutes dwell period. Dialysis had been well tolerated apart from a single episode of peritonitis. He had residual renal function consisting of 1500 – 2000mL diuresis per day. On a routine follow – up visit he complained of a dry cough lasting 3 days and dyspnoea. Respiratory rate was 35 breaths/minute, heart rate was 110 beats / minute and his oxyhaemoglobin saturation was 94% in room air. Auscultation revealed attenuated breathing sounds over the lower half of the right chest and dullness was noted on percussion; he was afebrile and there was no evidence of heart failure or peripheral oedema. Chest radiography confirmed a massive right-sided pleural effusion with a



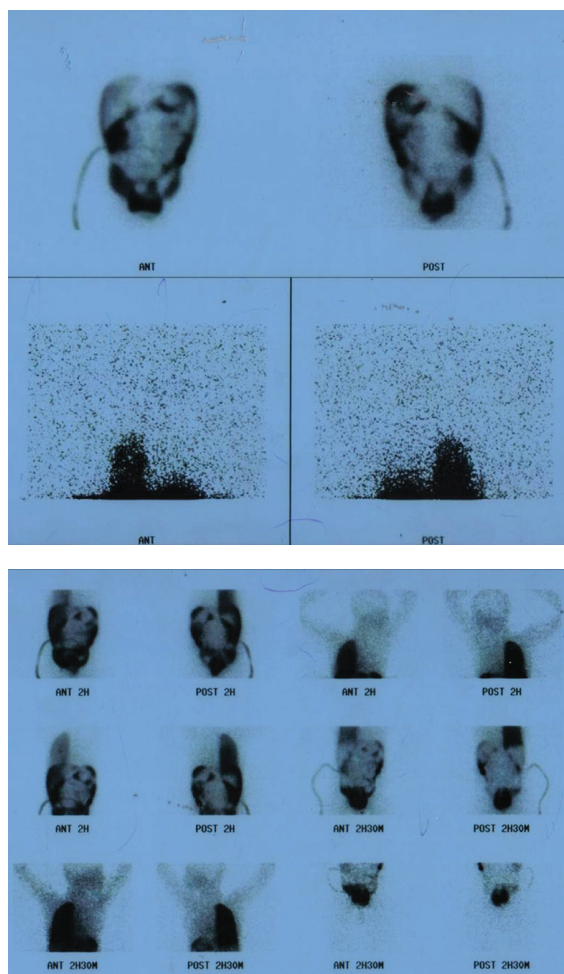
**Figure 1:** Chest radiograph showing a massive right-sided pleural effusion

cardiac silhouette of normal size (figure 1). Insertion of a chest drain was uneventful and aspirated 3.6 Litres of straw-coloured pleural fluid over 24 hours. The results of simultaneously drawn serum and pleural fluid are shown in table 1. Bacterial and mycobacterial cultures were negative. To prevent the hydrothorax from enlarging the dialysate dextrose concentration was initially increased to 2.27%, the mean exchange volume was decreased to 500 mL / cycle (15 mL / Kgr), the dwell period was shortened to 40 min and the patient was advised to adopt a semi-sitting position during dialysis. Peritoneal scintigraphy with Technetium-99m macroaggregated human albumin (Tc-99m MAA) revealed diffusely increased isotopic activity in the right hemithorax (figures 2a & 2b), confirming the suspected presence of a pleuroperitoneal communication. Magnetic Resonance Imaging (MRI) failed to demonstrate the communication. APD was temporarily interrupted as pleural effusion continued even with smaller cycle volume, and the patient was transferred temporarily to haemodialysis. APD was resumed 6 weeks later, without clinical or radiographic recurrence of the effusion.

### Discussion

Acute hydrothorax is a rare complication of PD. The first case of pleural effusion during APD has been reported by Edward and Unger in 1967<sup>2</sup>, whereas Lorenz published the first paediatric cases in 1979<sup>3</sup>. The incidence reported varies from 0.9%<sup>4</sup> to 20%<sup>1</sup>; most authorities give an estimate of 2-3%. In our tertiary University Paediatric Department this is the first case of APD-related hydrothorax over 20 years. During this period 63 children (aged 1 month to 18 years) received APD both for acute and chronic renal failure.

It usually affects the right hemithorax and there is no clear sex predominance<sup>4</sup>. Bilateral hydrothoraces in



**Figure 2a & 2b:** Peritoneal scintigraphy with Technetium-99m macroaggregated human albumin (Tc-99m MAA) revealed diffusely increased isotopic activity in the right hemithorax

children on peritoneal dialysis are very rare. The interval between onset of CAPD and development of a pleural effusion can range from a few hours to 8 years<sup>4</sup>. It has been suggested that it is more common in children receiving APD for acute renal failure secondary to haemolytic uraemic syndrome<sup>1,5</sup>. Krishan et al reported that a major factor in the development of an acute hydrothorax with APD appears to be starting to cycle with 40 mL/kg volumes, whereas increasing to this volume from initial 10 mL/kg cycles over 6 days prevents hydrothorax<sup>5</sup>. However in our case the child was on stable peritoneal dialysis prescription for the last six months with an exchange volume less than 40ml/kg

Clinical presentation can vary from being a serendipitous discovery in asymptomatic children to respiratory compromise in children in extremis<sup>1</sup>. Our patient was identified during regular follow up. Most children report retention of the dialysate, cough, dyspnoea and costal discomfort. The presence of the effusion can be confirmed by radiography and sonography. The clinician

**Table1:** Results of chemical analysis of simultaneously drawn serum and pleural fluid

	Serum	Pleural Fluid
Glucose (mg/dl)	91	312
Total protein (g/dl)	6.8	0.3
Lactic dehydrogenase (U/L)	218	32

may face difficulties in the differential diagnosis of APD-related hydrothorax when other potential aetiologies of transudative effusions may coexist, such as inadequate ultrafiltration, hypoalbuminaemia, congestive cardiac failure, or tuberculosis pleurisy, especially in chronic cases<sup>6</sup>. Therefore, meticulous attention to history taking and clinical examination is of utmost importance. Failure to recognise this entity may lead to inadvertent prescription of hypertonic dialysis exchanges, with grave consequences<sup>7</sup>

Hydrothorax in this context is rightfully called “sweet hydrothorax” as hypertonic glucose solution fills the pleural space. Therefore, the hallmark of the diagnosis is demonstrating a positive pleural fluid to serum glucose concentration gradient<sup>7</sup>. In the patient presented herein, glucose concentration in the pleural fluid aspirate was more than three times higher than that in the serum at the same time. The pleural fluid glucose concentration can vary substantially, depending on the size of the pleuroperitoneal communication, the rate of glucose absorption from the pleural space, the concentration gradient between the two compartments and the timing of the thoracocentesis<sup>7</sup>.

The pathogenesis of APD-related hydrothorax remains unclear; the most likely explanation is the unidirectional flow of the peritoneal fluid via congenital or acquired diaphragmatic defects<sup>6,8,9</sup>. Contrast studies via the dialysis catheter, peritoneal isotopic studies or even direct inspection at surgery do not always reveal a communication<sup>4</sup>. In our patient Tc-99m MAA scintigraphy was helpful. Alternative mechanisms that have been postulated include passage of fluid to the pleural cavity through lymphatic channels in the diaphragm or lymphatic leakage from the thoracic duct<sup>6</sup>.

Various therapeutic approaches have been proposed. Nomoto et al reported complete resolution of the hydrothorax following brief interruption of the APD— as was the case in the patient presented herein— in 19 out of 50 patients in a large retrospective study<sup>4</sup>. They speculated that this brief interruption allowed the diaphragmatic defect responsible for the pleuroperitoneal communication to heal and made return to APD feasible. Reduced volume dialysis has also been used with success Pleurodesis with tetracycline, autologous blood, or other sclerosing agents instilled into the pleural cavity via thoracic tubes have been proposed in order to allow resumption of full volume APD in patients in whom conservative medical management had failed. Recent advances in video assisted thoracoscopic surgery (VATS) promise great advances both in treating visible lesions such as diaphragmatic

blebs<sup>10</sup> and also mechanical<sup>9</sup> or chemical<sup>8</sup> thoracoscopic pleurodesis.

To conclude, clinicians involved in the treatment of children on APD must have a high index of suspicion for this rare, but potentially life threatening complication.<sup>10</sup>

### References

1. Butani L, Polinsky MS, Kaiser BA, Baluarte HJ. Pleural effusion complicating acute peritoneal dialysis in hemolytic uremic syndrome. *Pediatr Nephrol.* 1998; 12:772-774.
2. Edward SR, Unger AM. Acute hydrothorax - a new complication of peritoneal dialysis. *JAMA.* 1967; 199:853-855.
3. Lorentz WB. Acute hydrothorax during peritoneal dialysis. *J Pediatrics.* 1979; 94:417-419.
4. Nomoto Y, Suga T, Nakajima K, Sakai H, Osawa G, Ota K, et al. Acute hydrothorax in continuous ambulatory peritoneal dialysis-a collaborative study of 161 centers. *Am J Nephrol.* 1989; 9:363-367.
5. Krishnan RG, Ognjanovic MV, Crosier J, Coulthard MG. Acute hydrothorax complicating peritoneal dialysis. *Perit Dial Int.* 2007; 27:296-299.
6. Huang J, Wu J, Chi W, Lan R, Yang L, Chiu N. Hydrothorax in continuous ambulatory peritoneal dialysis: therapeutic implications of Tc-99m MAA peritoneal scintigraphy. *Nephrol Dial Transplant.* 1999; 14:992-997.
7. Chow KM, Szeto CC, Wong TY, Li PK. Hydrothorax complicating peritoneal dialysis: diagnostic value of glucose concentration in pleural fluid aspirate. *Perit Dial Int.* 2002; 22:525-528.
8. Yen H-T, Lu H-Y, Liu HP, Hsieh M-J. Video-assisted thoracoscopic surgery for hydrothorax in peritoneal dialysis patients -- check-air-leakage method. *Eur J Cardiothorac Surg.* 2005; 28:648-649.
9. Tsunozuka Y, Hatakeyama S, Iwase T, Watanabe G. Video-assisted thoracoscopic treatment for pleuroperitoneal communication in peritoneal dialysis. *Eur J Cardiothorac Surg.* 2001; 20:205-207.
10. Wang H-B, Kao C-C, Hsu K-F, Yang M-H, Yu H-C, Chen J-C. Diaphragmatic Bleb Complicated Hydrothorax in Peritoneal Dialysis. *Internal Medicine.* 2009; 48:1333-1334.