

## The clinical presentation of Von Meyenburg complexes

Sinakos E<sup>1</sup>, Papalavrentios L<sup>1</sup>, Chourmouzi D<sup>2</sup>, Dimopoulou D<sup>1</sup>, Drevelegas A<sup>2</sup>, Akriviadis E<sup>1</sup>

<sup>1</sup>4<sup>th</sup> Department of Internal Medicine, Aristotle University of Thessaloniki, Greece

<sup>2</sup>Department of Radiology, Aristotle University of Thessaloniki, Greece

### Abstract

Von Meyenburg Complexes (VMCs) is a rare clinicopathologic entity, consisting of small (<1.5cm), usually multiple and nodular cystic lesions. VMCs typically cause no symptoms or disturbances in liver function and thus in most instances they are diagnosed incidentally. We present four VMCs cases, each with a distinct clinical presentation. In two of our cases, VMCs caused mild, non-specific abdominal symptoms, including diffuse abdominal pain and discomfort. In the other two cases, in a 60-year-old woman and a 25-year-old man, the clinical presentation was implicative of an infectious hepatic process reminiscent of cholangitis and liver abscesses respectively. In each case the diagnosis was based on magnetic resonance imaging and magnetic resonance cholangiopancreatography findings showing multiple hyper-intense cystic nodules not communicating with the biliary tree. Physicians should be aware of the entire clinical spectrum of VMCs and its unique radiologic features in order to differentiate VMCs from other cystic liver lesions. Hippokratia 2011; 15 (2): 170-173

**Key words:** von Meyenburg complexes, liver cysts, bile duct hamartomas, clinical presentation

**Corresponding author:** Emmanouil Sinakos, 11A Perdika Str, Pilea, Thessaloniki, 55535, Greece; tel.: +302310315717; e-mail: em\_sinakos@yahoo.com

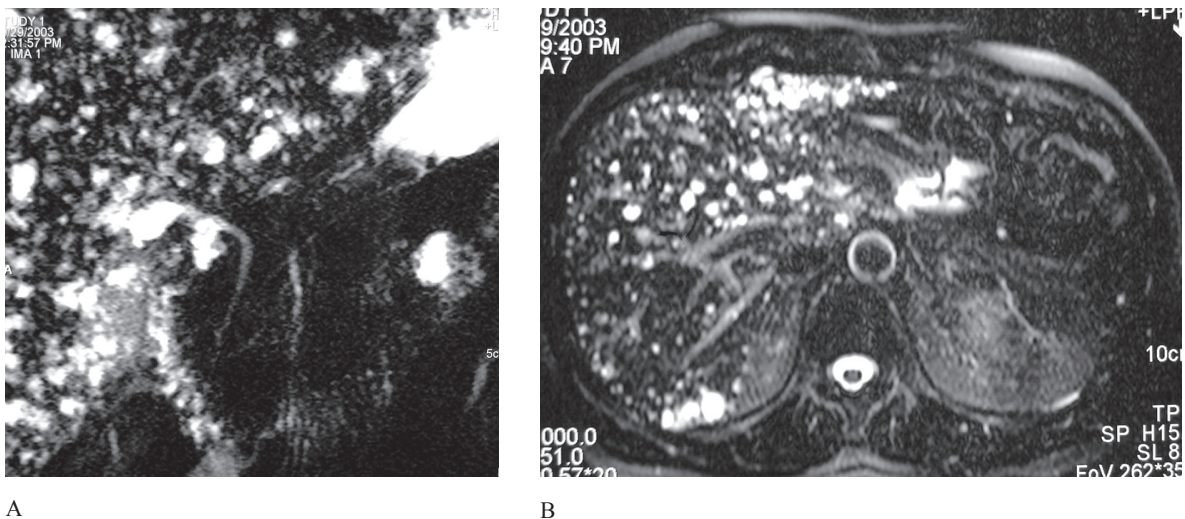
The presence of multiple liver cystic lesions can occasionally represent a diagnostic dilemma. Multiple simple liver cysts are by far the most common etiology. Occasionally, however, multiple parasitic liver cysts or Caroli's disease can cause diagnostic uncertainties; rarely, liver metastatic disease, causing necrosis of the affected liver parenchyma, has to be excluded.

In this setting, Von Meyenburg Complexes (VMCs) is a rare clinicopathologic entity, consisting of small (<1.5cm), usually multiple and nodular, cystic lesions, which are caused from ductal plate malformations of

the smallest intrahepatic bile ducts<sup>1</sup>. These lesions typically cause no symptoms or disturbances in liver function and thus, in most instances, VMCs are diagnosed incidentally, on the basis of their unique radiologic appearance<sup>2</sup>.

However, VMCs have been associated clinically with a variety of symptoms, therefore posing diagnostic challenges, especially at the time of their initial presentation<sup>3,4</sup>.

We present a series of four patients with VMCs, each one with a distinct clinical presentation.



**Figure 1: (AB)** MRI and MRCP appearance of multiple cystic liver lesions consistent with VMCs.

**Case 1**

A 55-year-old man was admitted with a 6-month history of diffuse abdominal pain. Abdominal computed tomography (CT) scan, which was carried out while the patient was being investigated in an outpatient basis revealed multiple liver cysts. Physical examination showed no abnormal findings and symptoms remained stable and generally mild during hospitalization. Laboratory tests were normal. Diagnostic work-up was completed with magnetic resonance imaging (MRI) and magnetic resonance cholangiopancreatography (MRCP), which confirmed the presence of multiple cystic liver lesions with maximum size of 1.5cm. These lesions had no communication with the bile ducts and fulfilled the diagnostic criteria of VMCs (Figure 1).

**Case 2**

A 52-year-old woman was evaluated in our out-patient clinic for multiple liver cystic lesions, found incidentally on ultrasound examination. The patient complained of non-specific abdominal pain and discomfort for several months prior to evaluation, without any symptoms suggestive of biliary liver disease. Past medical history was not significant for any serious medical or surgical conditions and all laboratory tests were normal. An MRI-MRCP scan was performed and confirmed the presence of multiple cystic lesions, typical of VMCs; they ranged in size between 0.5 and 1cm and showed no evidence of communication with the bile ducts (Figure 2).

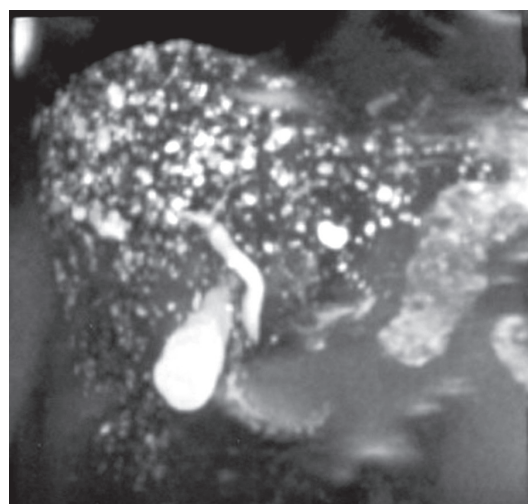
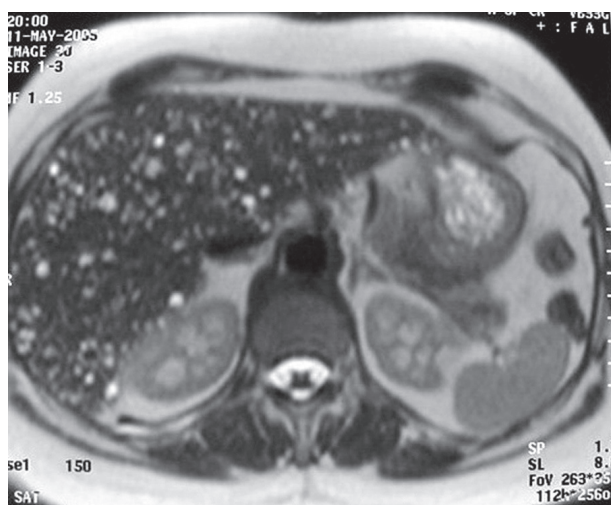
**Case 3**

A 60-year-old woman was admitted with a three-day history of right-upper quadrant abdominal pain, fever and jaundice. The past medical history revealed cholecystectomy and choledocholithiasis with papillotomy and removal of gall stones from the common bile duct which took place 10 years ago. Clinical examination showed no major abnormalities, apart from mild, right-upper quad-

rant, abdominal tenderness. Laboratory findings showed significant liver enzyme elevations (AST=291 IU/L, ALT=436 IU/L,  $\gamma$ GT=587 IU/L, ALP=741 IU/L); total bilirubin was 6.5 mg/dL. MRCP ruled out obstructive biliary lesions and MRI revealed the presence of multiple liver cystic lesions with maximum size of 1.5cm. The radiologic features of these lesions were typical of VMCs (Figure 3). Although there were no findings suggestive of extrahepatic obstruction in MRCP, endoscopic retrograde cholangiopancreatography (ERCP) was performed; it showed no evidence of recurrent choledocholithiasis or any other obstructive biliary lesions. The patient was treated with IV fluids and antibiotics. Complete clinical and biochemical resolution was noted over the following 10 days. She is free of symptoms the last three years.

**Case 4**

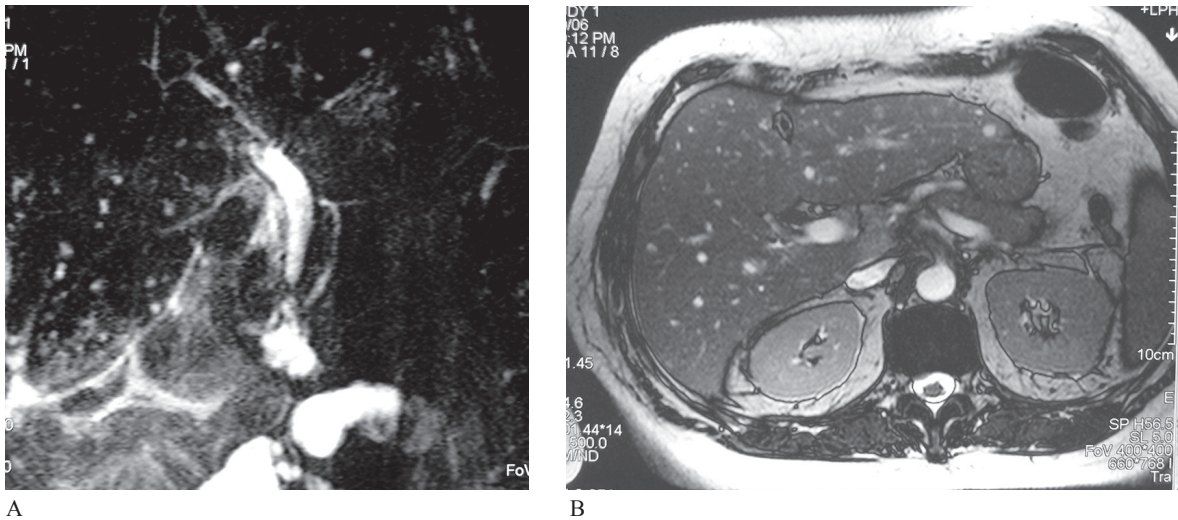
A 25-year-old man was admitted with a 30-day history of fever. His disease began with fatigue and epigastric discomfort. On admission, tenderness on liver percussion was present. Physical examination was otherwise normal. Complete laboratory evaluation including cultures, specific serologic assays for bacterial and viral infections (including CMV and EBV), immunologic assays and ASTO were normal, apart from elevated liver enzymes (AST= 61 IU/L, ALT= 80 IU/L), mild thrombocytopenia (131.000/mm<sup>3</sup>) and elevated ESR (60mm/h) and C-reactive protein (33 [normal <5mg/dl]) levels. Multiple liver cysts were the only finding of CT scans of the thorax and abdomen. Subsequent MRI-MRCP scans excluded the presence of choledocholithiasis and common bile duct dilatation while it revealed the presence of multiple liver cystic lesions, with radiologic features typical of VMCs (Figure 4). Fever and liver enzyme abnormalities initially responded to a four week course of antibiotics. However, fever recurred two weeks after withdrawal of antibiotics.



A

B

**Figure 2: (AB)** MRI and MRCP appearance of cystic liver lesions with no communication with the bile ducts.



**Figure 3:** A) Normal bile ducts on MRCP; B) cystic liver lesions consistent with VMCs.

A three month course of cyclic per os antibiotic regimen, including a third generation cephalosporin, ciprofloxacin and doxycycline, was subsequently administered with sustained defervescence and normalization of liver enzymes. One year after the completion of treatment the patient remains asymptomatic with normal laboratory tests.

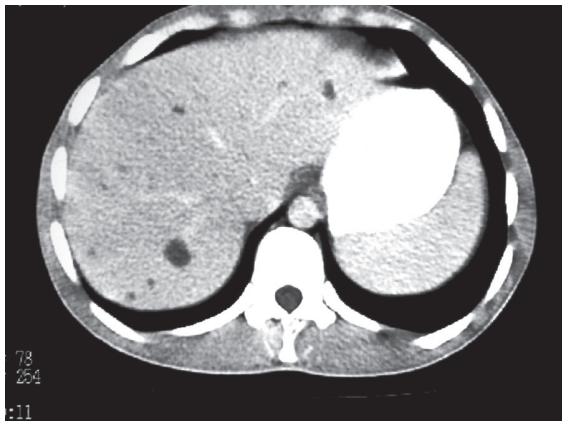### Discussion

VMCs, also known as “bile duct microhamartomas”, were first described in 1918<sup>5</sup>. They are small (<1.5cm), usually multiple, grayish, nodular lesions resulting from ductal plate malformations of the smallest intrahepatic bile ducts due to disordered embryonic involution<sup>1</sup>. They are related to autosomal dominant polycystic kidney disease, Caroli’s disease and congenital hepatic fibrosis<sup>6</sup>. Histologically, they are cystically dilated bile ducts lined by a single layer of regular cuboidal epithelium embedded in a collagenous stroma<sup>7</sup>.

VMCs used to be an incidental finding in laparoscopic procedures or in autopsies with a prevalence ranging from 0.7% to 2.8%<sup>8</sup>. With the recent advent of noninva-

sive imaging modalities (ultrasound, CT and MRI), they can now be diagnosed in non-surgical clinical practice, as well. In this setting, VMCs should be differentiated from Caroli’s disease and liver metastatic disease. On ultrasound, VMCs are shown as multiple hyper- or hypo-echoic areas with comet tail echoes. The CT appearance of VMCs consists of multiple, irregular, small, low attenuated areas, that do not normally enhance on contrast injection<sup>9,10</sup>. MRI of the liver and MRCP are superior to ultrasound and CT in diagnosing these lesions, showing multiple irregularly delineated hyper-intense cystic nodules, not communicating with the biliary tree<sup>11</sup>. Intravenous gadolinium administration is required, since contrast enhancement differentiates VMCs from Caroli’s disease. Liver biopsy is not contraindicated and should be performed if diagnosis is in doubt, especially in oncology patients<sup>4,12,13</sup>. Malignant transformation of these lesions has been described, particularly to cholangiocarcinoma, thus leading to the recommendation for periodical follow-up of these patients<sup>14</sup>. Notably, molecular evidence for the neoplastic potential of VMCs has been recently reported<sup>15</sup>.

VMCs do not usually cause symptoms or abnormalities in liver tests, but rarely they can present as episodes of recurring cholangitis or with infectious complications<sup>3,4</sup>. The clinical presentation in two of our patients (cases 1 and 2) was subtle characterized by non-specific abdominal discomfort. However, the clinical presentation in the other two patients (cases 3 and 4) was implicative of an infectious complication involving the liver parenchyma. Nonetheless, there was no suspicion for tumor presence in either case and the MRI findings were typical of VMCs, thus making a guided liver biopsy unnecessary. In case 3, symptoms and signs reminiscent of cholangitis were present. Although this patient had a history of choledocholithiasis treated 10 years previously with ERCP, recurrent choledocholithiasis was ruled out by MRCP and subsequently with a normal ERCP. The prompt response



**Figure 4:** MRI appearance of multiple cystic liver lesions with typical of VMCs radiologic features.

to IV antibiotics and the uneventful long-term course also suggest that recurrent choledocholithiasis was not the cause of liver sepsis in this patient. Interestingly, in case 4 the infectious process required long-term antimicrobial therapy, similar to that commonly applied for multiple liver abscesses. Although material from the cysts was not obtained for laboratory tests, it can be assumed that the magnitude and the duration of infectious process in both cases possibly resulted from superinfection of the cystic content.

In conclusion, VMCs is an overall rare finding of the liver with unique MRI appearance. VMCs usually cause no symptoms or liver function test abnormalities, but they can occasionally present with either non-specific abdominal symptoms or episodes of liver sepsis. Clinicians should be aware of this clinicopathologic entity and its clinical presentation and MRI and MRCP findings in order to be able to differentiate VMCs from other cystic diseases of the liver.

All participating authors have no conflict of interest to declare.

#### References

1. Desmet VJ. Congenital diseases of intrahepatic bile ducts: variation on the theme "ductal plate malformation". *Hepatology*. 1992; 16: 1069-1083.
2. Redston MS, Wanless IR. The hepatic von Meyenburg complex: prevalence and association with hepatic and renal cysts among 2843 autopsies. *Mod Pathol*. 1996; 9: 233-237.
3. Tan A, Shen J F, Hen AH. Sonogram of multiple bile duct hamartomas. *J Clin Ultrasound*. 1989; 17: 667-669.
4. Shu-Chen W, Guan-Tarn H, Chien-Hung C, Jin-Chuan S, Yuk-Ming T, Hey-Chi chen H, et al. Bile duct hamartomas: A report of two cases. *J Clin Gastroenterol*. 1997; 25: 608-611.
5. von Meyenburg H. Uber die Cystenleber. *Beitr Pathol Anat* 1918; 64: 447-532.
6. Leuven KU, Desmet VJ. Pathogenesis of ductal plate malformation. *J Gastroenterol Hepatol*. 2004; 19: 356-360.
7. Zen Y, Terahata S, Miyayama S, Mitsui T, Takehara A, Miura S, et al. Multicystic biliary amartoma: a hitherto underdescribed lesion. *Hum Pathol*. 2006; 37: 339-344.
8. Salo J, Bru C, Vilella A, Ginòs P, Gilabert R, Castells A, et al. Bile duct hamartomas presenting as multiple focal lesions on hepatic ultrasonography. *Am J Gastroenterol*. 1992; 87: 221-223.
9. Zheng RQ, Zhang B, Kudo M, Onda H, Inoue T. Imaging findings of biliary hamartomas. *World J Gastroenterol*. 2005; 13: 6354-6359.
10. Luo TY, Itai Y, Eguchi N, Kurosaki Y, Onaya H, Ahmadi Y, et al. von Meyenburg complexes of the liver: imaging findings. *J Comput Assist Tomogr*. 1998; 22: 372-378.
11. Mortelet B, Mortelet K, Seynaeve P, Vandeveld D, Kunnen M, Ros PR. Hepatic bile duct hamartomas (von Meyenburg complexes): MRI and MR cholangiography findings. *J Comput Assist Tomogr*. 2002; 26: 438-443.
12. Eisenberg D, Hurwitz L, Yu AC. CT and sonography of bile duct hamartomas simulating malignant liver disease (case report). *AJR*. 1986; 147: 279-280.
13. Davidoff S, Kim S, Friedman B. von Meyenburg complexes (bile duct hamartomas). *Clin Gastroenterol Hepatol*. 2006; 4: A26.
14. Jain D, Sarode VR, Abdul-Karim FW, Homer R, Robert ME. Evidence for the neoplastic transformation of von-Meyenburg complexes. *Am J Surg Pathol*. 2000; 24: 1131-1139.
15. Jain D, Ahrens W, Finkelstein S. Molecular evidence for the neoplastic potential of hepatic Von-Meyenburg complexes. *Appl Immunohistochem Mol Morphol*. 2010; 18: 166-171.