

## Atypical hemolytic-uremic syndrome (HUS) with recovery after a long-lasting anuria: a case report

Georgaki-Angelaki H<sup>1</sup>, Stergiou N<sup>1</sup>, Kapogiannis A<sup>1</sup>, Orfanou I<sup>2</sup>, Grapsa B<sup>3</sup>, Roma E<sup>2</sup>

<sup>1</sup>Department of Pediatric Nephrology "Aghia Sophia" Children's Hospital, Athens, Greece

<sup>2</sup>First Department of Pediatrics, Athens University Medical School, Athens, Greece

<sup>3</sup>"Alexandra" Maternity Hospital, Plasmapheresis Unit, Athens, Greece

### Abstract

We report a case of a seven-year-old girl who suffered from atypical Hemolytic Uremic Syndrome (aHUS) complicated by septicemia, central nervous system involvement, and cholangitis. She remained anuric requiring treatment with peritoneal dialysis (PD) for a five-month period. In addition to conventional therapeutic measures including fresh frozen plasma (FFP) and blood cells transfusions she also underwent to plasma exchange (PE) treatment. Following a stormy hospitalization period of 17 weeks, the patient finally regained renal function and three years later she remains well on antihypertensive treatment and free of dialysis. Hippokratia 2011; 15 (1): 90-92

**Key Words:** atypical Hemolytic Uremic Syndrome, anuria, cholangitis, seizures

**Corresponding author:** Helen Georgaki-Angelaki, Department of Pediatric Nephrology "Aghia Sophia" Children's Hospital, Athens, Greece, Tel & Fax :+ 210 7467097; E-mail: pedneph@paidon-agiasofia.gr

About 10% of overall HUS patients present with the atypical form of the disease. This comprises a heterogeneous group of patients with a rather severe phenotype, usually characterized by oligoanuria, hypertension and central nervous system involvement<sup>1-3</sup>. Long term prognosis is poor with high morbidity and mortality.

If these patients survive, they go into chronic replacement therapy or chronic renal failure at a rate of 34.5% and 31% respectively<sup>3,4</sup>. Recovery of renal function following long lasting dialysis in children suffering from aHUS has been rarely reported<sup>5,6</sup>.

We report a case of a seven-year-old girl who suffered from aHUS, complicated by septicemia, central nervous system involvement, and cholangitis with recovery, following a five month period on PD.

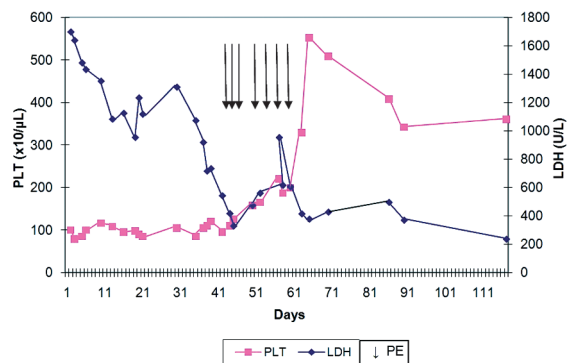
### Case report

A seven-year-old girl was admitted to "Aghia Sophia" children's hospital with a two-day history of macroscopic hematuria, abdominal pain, headache and a low grade fever. Two weeks earlier skin eruption attributed to an allergic reaction was reported, and treatment with oral steroids was given for a week. On examination she was pale and icteric with a faded maculopapular eruption on her arms and palms. There was no history of diarrhoea or bloody stools. Laboratory results revealed anaemia (hematocrit 20.9%, hemoglobin 6.7g/dl, leukocytes  $9 \times 10^3/\mu\text{l}$ ) with fragmented red cells (schistocytes) and reticulocytes (7.5%), thrombocytopenia (platelets  $63 \times 10^3/\mu\text{l}$ ), hyperbilirubinemia (serum bilirubin 3.2mg/dl), lactate dehydrogenase (LDH) 580U/L (normal 150-450U/L) and acute renal failure (plasma creatinine 3.8 mg/dl), with estimated GFR (eGFR) 13ml/min/1.73m<sup>2</sup>. A de-

crease of serum C3 complement level was found (63.2 mg/dl, normal 90-180 mg/dl). Her urinalysis revealed macroscopic hematuria and four (+) proteinuria. Renal ultrasonography revealed two normal sized kidneys with increased echogenicity. The diagnosis of diarrhea-negative hemolytic uremic syndrome was made and she was treated with fresh frozen plasma (FFP) infusions (20ml/Kg/day) along with red packed cells. Due to the positive ANA titers (1/320) a percutaneous renal biopsy was performed in order to exclude lupus related HUS. In 5 out of 17 glomeruli examined, thickening and duplication of basement membrane wall with endothelial swelling was found.

Tubules and interstitium revealed areas with ischemic lesions. Extreme luminal narrowing due to intimal proliferation and intraluminal platelet thrombi in vessels, mainly glomerular capillaries and efferent arterioles was identified. A positive deposition of IgM ++ and C3 +++ was found on immunofluorescence. There was no cortical necrosis and the above findings confirmed the diagnosis of non-lupus related HUS.

On the tenth post-admission day the patient became oligoanuric with a plasma creatinine 6.2mg/dl and urea 300mg/dl and treatment with PD were conducted. Six weeks later, while on PD, acute hemolysis and thrombocytopenia remained unchanged (LDH levels 1073 IU/l and platelets  $<90 \times 10^3/\mu\text{l}$  respectively, Figure 1). The need for an alternative treatment with PEs was prompt. This treatment was performed on a daily or alternate day basis for two weeks, replacing the patient's plasma with FFP at a rate of 30ml/Kg per session. After a total of seven sessions, the most encouraging results in terms of platelet count rising up to  $220 \times 10^3/\mu\text{l}$  and



**Figure 1:** LDH-PLTs fluctuations during the course of the disease.

LDH levels dropping down to 326 IU/I were observed. However, PE treatment had to be stopped due to a central venous catheter infection followed by septicemia. Her clinical condition was deteriorated with development of malignant hypertension refractory to a cocktail of antihypertensive regimen including calcium channel blockers, ACE inhibitors, and beta-blockers, while severe headache, confusion and grand mal seizures were added.

Following a stormy period of more than two months, the patient's condition improved again but a week later she suffered from a severe episode of cholangitis presented with fever, hyperbilirubinemia (serum bilirubin 4.4mg/dl with direct 3.4 mg/dl), and increased serum levels of SGOT, SGPT and  $\gamma$ GT (293U/L, 195U/L, 1976 U/L respectively) confirmed by abnormalities appearing on an abdominal CT scan and ultrasonography. After appropriate medical management she recovered from these complications. Having been an inpatient for sixteen weeks on PD, but with no more signs of hemolysis with normal LDH and platelets she was discharged home on CAPD. On week 19 she started passing urine with gradual improvement of her renal function to the degree that CAPD was no longer necessary. Recent investigation of the complement components including C3 Ag, C4 Ag, factor B Ag, factor H Ag, factor I Ag, Anti-FH Ab and CD46 was performed, showing normal results, although the C3 Ag level was for both, the patient and her father, at the lower normal range thus indicating the role of genetic complement abnormalities. At her last follow-up, three years later, she was in a good clinical condition, attending school on a regular basis, without cognitive or other abnormalities. Her plasma creatinine was 1.2mg/dl and eGFR of 55ml/min/1.73m<sup>2</sup>. Blood pressure remains well controlled on a ACE inhibitor

(Enalapril tabl 20mg every morning) and Calcium channel blockers (Nifedipine tabl 20mg noon time and Felodipine tabl 5 mg in the evening) and her urinalysis is normal.

## Discussion

Our patient represents a sporadic case of aHUS and

fulfilled all criteria for a severe form of this disease. During her illness she experienced a number of complications such as septicaemia, refractory hypertension, central nervous system involvement and cholangitis. She was also in an oligoanuric status for almost five months. Under the above described clinical condition this aHUS case fell into the poor prognostic group<sup>7</sup>. Indeed, it has been suggested, that a long standing period on renal replacing therapy consists of a poor prognostic factor for the recovery of renal function<sup>8,9</sup>. In contrast to this expectation, this emphasises the fact, already described by others, that children with HUS, who require a longer time for renal function recovery do not necessarily have a worse prognosis<sup>10</sup>.

Data regarding the HUS affected children who experienced renal function recovery following long period on dialysis, are limited<sup>5,6</sup>. Included among them there are two cases who remained anuric for 14 and 52 weeks, respectively, and came off dialysis with incomplete recovery of renal function<sup>5</sup> and two further cases who also recovered following 8 and 16 months on long lasting dialysis treatment<sup>6</sup>. PEs consist treatment modality, successfully used in adults with thrombotic thrombopenic purpura-haemolytic uremic and the rationale to extend it's use in children with HUS was based on already known beneficial results<sup>11</sup>. Furthermore, it has been stated that PEs can shorten the duration of acute renal failure and lead to a better long term prognosis. This treatment is especially advantageous for patients suffering from post diarrhoeal syndrome with central nervous system involvement<sup>12,13</sup>. It remains unclear, whether by this potentially injurious and not established form of treatment, the toxic factor or factors are eliminated, and therefore contributing to a better prognosis. In any case, the fact that we were dealing with a severely ill child, prompted us to continue treatment with PEs, as a proper alternative to FFP infusions. It seems clear from our data that following initiation of PEs,

the LDH and platelets levels improved gradually and this steady state situation remained stable for both parameters throughout the course of the disease (fig 1). However, it is difficult to associate patient's renal function recovery with PEs, since between these two events there was an interval of three months. The extent to which both FFP and PEs as therapeutic interventions, effectively accelerated renal function recovery remains an unanswered question. The debate regarding the presence of circulating factors or an unidentified deficiency plasma factor, or both, triggering endothelial damage, still exists. Our patient was tested for factor H deficiency and found to be normal. As it is known these genes are coding for proteins involved in regulation or activation of the alternative pathway of complement<sup>14,15</sup>.

This case seems to belong to a group of patients with aHUS, who although display no factor H mutation, 50% of them exhibit evidence of over activity of the alternative pathway of complement<sup>2</sup>. The finding of a low level of C3 component of complement in our patient during

the acute phase of the disease reflects probably C3 consumption in the renal microvasculature. Indeed, the immunofluorescence test on the renal biopsy specimen was consistent with a positive deposition of C3. It has been reported that among these patients the majority display a decreased C3 plasma level and up to 30% are carriers of mutations in the gene(s) encoding for factor H (HF1) and membrane cofactor protein (MCP), which is highly expressed in the kidney, and probably protecting it. However, the remainder of the aHUS patients, as in our case, do not carry HF1 mutation. The outcome of aHUS affected children is less predictable in comparison to D+ HUS cases and on average fairly unfavourable. However, data from renal pathology findings could be somehow predictive since it has been suggested that renal parenchyma lesions affecting less than 50% of the glomeruli at the initial phase constitutes a favourable prognostic factor<sup>16</sup>. Indeed, our patient's renal biopsy revealed 29% affected glomeruli and this is probably an additional prognostic finding contributing to the good outcome of this severely affected girl. In conclusion, we speculate that PEs contributed to the clinical improvement of this patient and in contrary to expectation regarding severely affected HUS children, a long lasting dialysis period does not exclude a favourable prognosis.

No conflict of interest was declared.

## References

1. Siegler RL, Oakes RS. Hemolytic uremic syndrome; pathogenesis, treatment, and outcome. *Curr Opin Pediatr.* 2005; 17: 200-204.
2. Noris M, Remuzzi G. Hemolytic uremic syndrome. *Am Soc Nephrol* 2005; 16: 1035-1050. 3. Proesmans W. Typical and atypical hemolytic uremic syndrome. *Kidney Blood Press Res.* 1996; 19: 205-08.
4. Fitzpatrick MM, Walters MD, Trompeter RS, Dillon MJ, Barratt TM. Atypical non-diarrhea-associated hemolytic-uremic syndrome in childhood. *J Pediatr.* 1993; 122: 532-537.
5. Trompeter RS, Schwartz, Chantler C, Dillon MJ, Haycock GB, Kay R, Barratt TM Atypical non-diarrhea-associated Haemolytic-uremic syndrome: an analysis of prognostic futures. *Arch Dis Child.* 1983; 58: 101-105.
6. Brunner K, Bianchetti MG, Neuhaus TJ. Recovery of renal function after long-term dialysis in hemolytic uremic syndrome. *Pediatr Nephrol.* 2004; 19: 229-231.
7. Tonshoff B, Sammet A, Sanden I, Mels O, Waldherr R, Scharer K. Outcome and prognostic determinants in the hemolytic uremic syndrome in children. *Nephron.* 1994; 68: 63-70.
8. Siegler RL, Milligan MK, Burningham TH, Christofferson R, Chang S, Jorbe L. Long-term outcome and prognostic indicators in the hemolytic-uremic syndrome. *J Pediatr.* 1991; 118: 195-200.
9. Oakes, RS, Kirkham JK, Nelson RD, Siegler RL. Duration of oliguria and anuria as predictors of chronic renal-related sequelae in post-diarrheal hemolytic-uremic syndrome. *Pediatr Nephrol.* 2008; 23: 1303-1308.
10. Cobepas CJ, Alkoncher LF, Spizzirri AP, Rahman RC. Long-term follow-up of Argentinean patients with hemolytic uremic syndrome who had not undergoing dialysis. *Pediatr Nephrol.* 2007; 22: 1343-1347.
11. Ruggenenti P, Noris M, Remuzzi G. Thrombotic microangiopathy, hemolytic uremic syndrome, and thrombotic thrombocytopenic purpura. *Kidney Intern.* 2001; 60: 831-846.
12. Gianviti A, Perna A, Caringella A, Edefonti A, Penza R, Remuzzi G, Rizzoni G. Plasma exchange in children with hemolytic-uremic syndrome at risk of poor outcome. *Am J Kidney Dis.* 1993; 22: 264-266.
13. Ruggenenti P, Remuzzi G. Pathophysiology and management of thrombotic microangiopathies. *J Nephrol.* 1998; 11: 300-310.
14. Neumann HP, Slazmann M, Bohnert-Iwan B, Mannuelian, T, Skerka C, Lenk D, et al. Hemolytic uremic syndrome and mutation for the factor H gene: a registry-based study of German speaking countries. *J Med Genet.* 2003; 40: 676-681.
15. Dragon-Durey MA, Frumeaux- Bacchi V. Atypical haemolytic uraemic syndrome and mutations in complement regulator genes. *Springer Semin Immun.* 2005; 27: 359-374.
16. Loirat C, Baudouin V, Sonsino E, Mariani-Kurdjian P, Elion J. Hemolytic uremic syndrome in the child. *Adv Nephrol Necker Hosp.* 1993; 22: 141-168.

## Bolus fluorouracil induced syncope and pulseless ventricular tachycardia: a case report

Fidan E<sup>1</sup>, Fidan S<sup>2</sup>, Yildiz B<sup>1</sup>, Durmus I<sup>3</sup>, Kavgaci H<sup>1</sup>, Ozdemir F<sup>1</sup>, Aydin F<sup>1</sup>

<sup>1</sup>Departments of Medical Oncology,

<sup>2</sup>Gastroenterology,

<sup>3</sup>Cardiology Faculty of Medicine, Karadeniz Technical University, Trabzon, Turkey

### Abstract:

5-fluorouracil is an anti-cancer drug commonly used in oncology practice. Typical side effects are myelosuppression, nausea, vomiting, diarrhea and stomatitis. Cardiotoxicity is the other toxicity. Cardiac side effects are ST segment changes, rhythm abnormalities, supraventricular and ventricular dysrhythmias. Pulseless ventricular tachycardia and ventricular fibrillation related with bolus fluorouracil were not detected in the literature. Here we discussed a 46 year-old male patient that has no known cardiac history. After bolus fluorouracil administration, syncope and pulseless ventricular tachycardia developed in this patient. There are a few explanations about the cardiotoxicity of fluorouracil. One of these is the effect on nitric oxide. It causes a reduction in the levels of endothelial NO and this leads coronary vasospasm. Another explanation is protein kinase C mediated vasospasm. In animal studies toxic myocarditis like lesions were detected with fluorouracil infusions. Finally both myocarditis and vasospasm may lead cardiac problems like sudden cardiac deaths. Bolus 5-fluorouracil is as cardiotoxic as 5-fluorouracil infusion and we must be careful about the arrhythmia after the bolus administration. Hippokratia 2011; 15 (1): 93-95

**Key words:** fluorouracil, arrhythmia, cardiac

**Corresponding author:** Evren Fidan, Karadeniz Technical University, Faculty of Medicine, Medical Oncology Department, 61080, Trabzon, Turkey, Tel: +90-462-3775023, Mob: +90-533-3449466, Fax: +90-462-3775023, E-mail: evrenfidan@yahoo.com

5-fluorouracil is an anti-cancer drug commonly used in oncology practice. It is used in the treatment of various cancers like breast, gastric, colorectal, head and neck, liver cancers. Typical side effects are myelosuppression, nausea, vomiting, diarrhea and stomatitis<sup>1</sup>. Cardiotoxicity is the other toxicity<sup>1</sup>. Cardiac side effects are ST segment changes, rhythm abnormalities, supraventricular and ventricular dysrhythmias<sup>2</sup>.

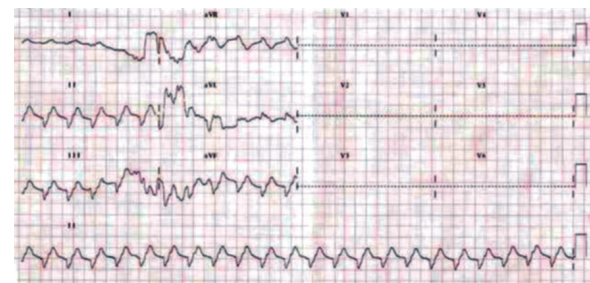Acute myocardial infarction was reported in the literature<sup>3</sup>. Pulseless ventricular tachycardia and ventricular fibrillation related with bolus fluorouracil were not detected in the literature. Here we discussed a 46 year-old male patient that has no known cardiac history. After bolus fluorouracil administration, syncope and pulseless ventricular tachycardia developed in this patient.

### Case report

A 46-year old male patient underwent subtotal gastrectomy because of the adenocarcinoma. He admitted to our out patient clinic postoperatively. Adjuvant chemoradiotherapy was planned due to the pathology report. His cardiological history was negative and he had no cardiac risk factors. In chemoradiotherapy programme 5-fluorouracil dose was 825 mg/day and folinic acid dose was 30 mg/day. The third day of the first cycle chemotherapy was administered to the patient but after 1 hour severe nausea and abdominal

pain developed. He admitted to the clinic and syncope was developed. Pulse was not detected and ECG showed pulseless ventricular tachycardia and ventricular fibrillation (Figure 1).

Defibrillation was performed and normal sinus rhythm was obtained. Physical examination showed an incision scar belonging to the operation. Electrolyte imbalance and hypoxia were not detected and his blood count was normal. Ejection fraction was evaluated by transthoracic echocardiography and it was 15%. After obtaining written consent, coronary angiography was performed in same day. A few plaques but not total occlusion or vasospasm were detected (Figure 2,3). In following days ventricular tachycardia, pulseless ventricular tachycardia and ventricular



**Figure 1:** Ventricular tachycardia when syncope was developed.