

Successful treatment of a spontaneous haemothorax with recombinant factor VIIa in a haemophilic child with inhibitors

Gidaris D, Economou M, Valeri R, Gombakis N, Athanasiou – Metaxa M

1st Paediatric Clinic, Hippokratio General Hospital, Aristotle University of Thessaloniki, Thessaloniki, Crece

Haemophilia A is an X-linked disorder caused by a deficiency of factor VIII. Haemorrhage in various sites may occur spontaneously or secondary to trauma depending on the severity of the deficiency. Common manifestations include haemarthrosis, epistaxis, gastrointestinal haemorrhage and haematuria. Spontaneous haemothorax has rarely been reported both in children and adults^{1,2}. We report the case of a haemophilic child presenting with spontaneous haemothorax due to the rarity of this clinical presentation in order to raise the awareness among clinicians. Hippokratia 2010; 14 (4): 289-290

Key words: haemophilia, haemothorax, inhibitors, prophylaxis, recombinant factor VIIa

Corresponding author: Dimos Gidaris, 9A, Pantazopoulou Street, Ampelokipi 56121, Thessaloniki, Greece, Tel: 00306947932194, e-mail: dgidaris@doctors.org.uk

Case report

A 6-year-old male haemophilic was admitted in our paediatric department because of presumed infection of his central venous access device (Hickman). Upon diagnosis he was started on recombinant factor VIII concentrate (Helixate[®] FS, CSL Behring), but due to development of high titre inhibitors (60 BU) and the occurrence of multiple haemarthroses, prophylaxis with recombinant factor VIIa (NovoSeven[®]) at a dose of 90 µg/Kg/day was commenced at the age of 5.5 years. Insertion of the Hickman catheter at that age had been uneventful. At presentation infection of the catheter was assumed because of pyrexia and ache during administration of NovoSeven[®]. Cultures were taken and the patient was promptly started on teicoplanin intravenously. Fever subsided following the second dose of teicoplanin. Staph. Saprophyticus sensitive to teicoplanin was isolated from the catheter culture, while blood cultures were negative. On day 3 of admission he presented with oedema and increased temperature of his left ankle which was managed with increasing administration of Novoseven[®] to 3 doses of 90 µg/kg given at 2 hour intervals. After that daily prophylaxis was restarted. On day 5 he complained of intense left sided chest pain. No trauma was reported. On examination he was afebrile, with decreased expansion of the left side of his thorax. On auscultation breath sounds on the left hemithorax were decreased and on percussion dullness was noted. Chest radiograph revealed opacification of the left hemithorax (figure 1) and chest ultrasonography confirmed the accumulation of clear fluid in the left pleural cavity without septa. He remained afebrile and haemodynamically stable. We opted not to tap the effusion and escalated administration of Novoseven[®] to 90 µg/kg given at 2 hours intervals until haemostasis was achieved. There was gradual improvement of the

clinical findings and a repeat chest radiograph and ultrasonography revealed significant reduction of the pleuritic fluid. NovoSeven[®] dosage was gradually weaned to the prior regimen of daily prophylaxis.

Discussion

Haemophilia is a rare genetic disorder that predisposes the patient to recurrent haemorrhages. Bleeding diathesis is due to deficiency of factor VIII; replacement of this factor in order to achieve haemostatically adequate levels is the mainstay of treatment. 5-15% of patients on replacement therapy develop inhibitors that neutralise the haemostatic effect of factor VIII^{3,4}. Incidence and prevalence of inhibitors are substantially higher in patients with severe haemophilia³.

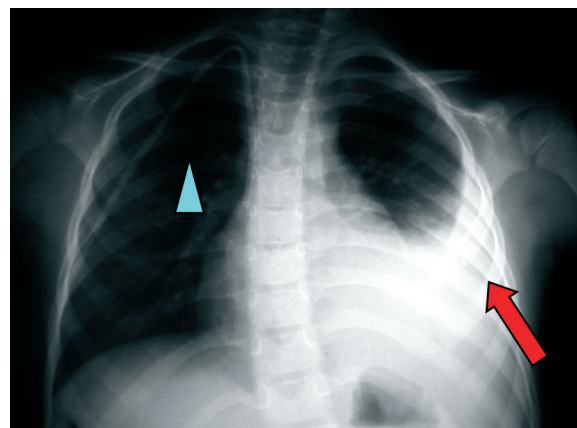


Figure 1: Chest radiograph (posteroanterior projection) performed to assess the cause of pleuritic chest pain. The arrow points to a left pleural effusion and the arrowhead points to the Hickman catheter.

The patient presented was initially admitted due to an infection of his central venous access device. This is a common problem in haemophiliacs and the risk is increased in the presence of inhibitors⁵, when the device used is external and when its insertion takes place between the age of 2 and 6⁶. Our patient had all the aforementioned risk factors. Infection of his central venous access device was controlled with the use of broad spectrum antibiotics.

The fascinating issue in this case is the development of a spontaneous haemothorax, i.e. without reported antecedent trauma. The patient was in hospital under close observation by the nursing staff and his mother when this unexpected complication occurred; this minimises the possibility of non disclosure of an accident. Spontaneous haemothoraces in adults have rarely been reported both in haemophilia A² and haemophilia B⁷. There are also sparse reports in children^{1, 8}. Consequently, there is no guideline in the paediatric literature regarding the optimal management of this rare presentation.

Our main therapeutic concern was whether conservative management in this child with high titre inhibitors would succeed. We opted not to drain the effusion because of the potentially devastating complications of uncontrollable bleeding. Success stories of conservative management have been published both with older and newer therapeutic modalities⁹. The rationale of conservative treatment is that in the absence of acute trauma, bleeding due to haemophilia consists of oozing⁸. Our patient made an uneventful recovery when recombinant factor VIIa was given every 2 hours. Recombinant factor VIIa has been shown to control haemorrhage in haemophilia A patients with high titre inhibitors in acute situations by complexing or binding with tissue factor to the cell surface of activated platelets either directly or indirectly¹⁰. An alternative therapeutic option in haemophiliacs with inhibitor presence is the use of activated prothrombin complex concentrate (FEIBA). Both re-

combinant factor VIIa and prothrombin complex concentrate are expensive treatments with variable clinical responses and potential thrombogenicity. Therefore their use should be judicious and only decided by highly specialised paediatric haematologists.

We report this case due to the rarity of this presentation in haemophilia in order to raise awareness among paediatricians and to highlight the availability of evolving therapeutic options in haemophiliacs with high titre inhibitors.

References

1. Obitko-Pludowska A, Laguna P, Adamowicz-Salach A, Brzewska M, Del Campo KS. Haemothorax in children with congenital coagulopathy. *Haemophilia*. 2010; 16: 688-691.
2. Burke JF, Salzman EW. Spontaneous hemopneumothorax in a hemophiliac. *J Am Med Assoc*. 1959; 169: 1623-1625.
3. Wight J, Paisley S. The epidemiology of inhibitors in haemophilia A: a systematic review. *Haemophilia*. 2003; 9: 418-435.
4. Castaman G. Prophylaxis of bleeding episodes and surgical interventions in patients with rare inherited coagulation disorders. *Blood Transfus* 2008; 6: s39-44.
5. Mancuso ME, Mannucci PM, Sartori A, Agliardi A, Santagostino E. Feasibility of prophylaxis and immune tolerance induction regimens in haemophilic children using fully implantable central venous catheters. *British Journal of Haematology*. 2008; 141: 689-695.
6. Valentino LA, Ewenstein B, Navickis RJ, Wilkes MM. Central venous access devices in haemophilia. *Haemophilia*. 2004; 10: 134-146.
7. Grabczak EM, Krenke R, Jeleńska M, Komarow I, Ambroziak U, Fangrat A, et al. Hemorrhagic parapneumonic effusion in a 64 year-old patient as the first symptom of hemophilia B. *Pneumonol Alergol Pol*. 2009; 77: 320-326.
8. Bulvik S, Barhum M, Burstein S, Tatarsky I. Conservative treatment of hemophiliac bleeding. *Harefuah*. 1990; 118: 632-634.
9. Hulíková M, Galajda P, Kubisz P. Successful treatment of hemothorax with recombinant factor VIIa in a hemophilic child with inhibitor. *Vnitr Lek*. 1988; 44: 547-550.
10. Ghosh N, Teefy P, Laudénbach L, Rivard GE. Cardiac tamponade in a patient with moderate hemophilia A and factor VIII Inhibitors. *Can J Cardiol*. 2006; 22:73-75.